A 47-year-old woman comes to the office due to fever, dysuria, and abdominal pain. She has had several episodes of urinary tract infections since her teens but no other medical problems. Physical examination reveals mild suprapubic discomfort. Urinalysis shows pyuria and many bacteria. A CT scan of the abdomen is obtained and is shown in the image below.

Which of the following most likely prevented the proper ascent of the anomalous organ seen on the CT scan?

- A. Inferior mesenteric artery
- B. Inferior vena cava
- C. Persistent urachus
- D. Superior mesenteric artery
- E. Vitellointestinal duct

Submit

Which of the following most likely prevented the proper ascent of the anomalous organ seen on the CT scan?

- ✓ A. Inferior mesenteric artery (79%)
- B. Inferior vena cava (1%)
- C. Persistent urachus (5%)
- D. Superior mesenteric artery (10%)
- E. Vitellointestinal duct (2%)

Omitted
Correct answer

79%
Answered correctly

07 secs
Time Spent

04/08/2020
Last Updated

Horseshoe Kidney

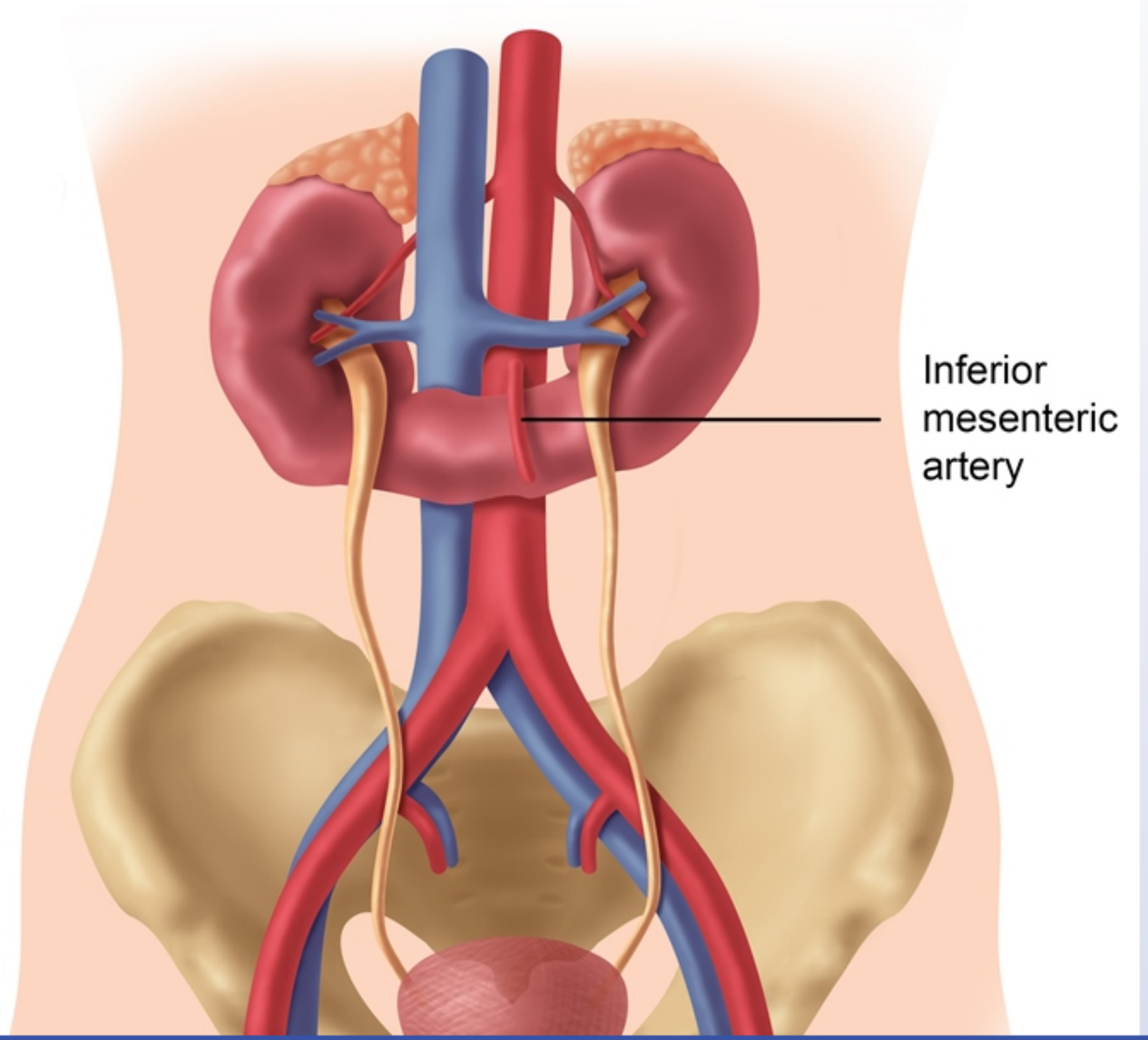

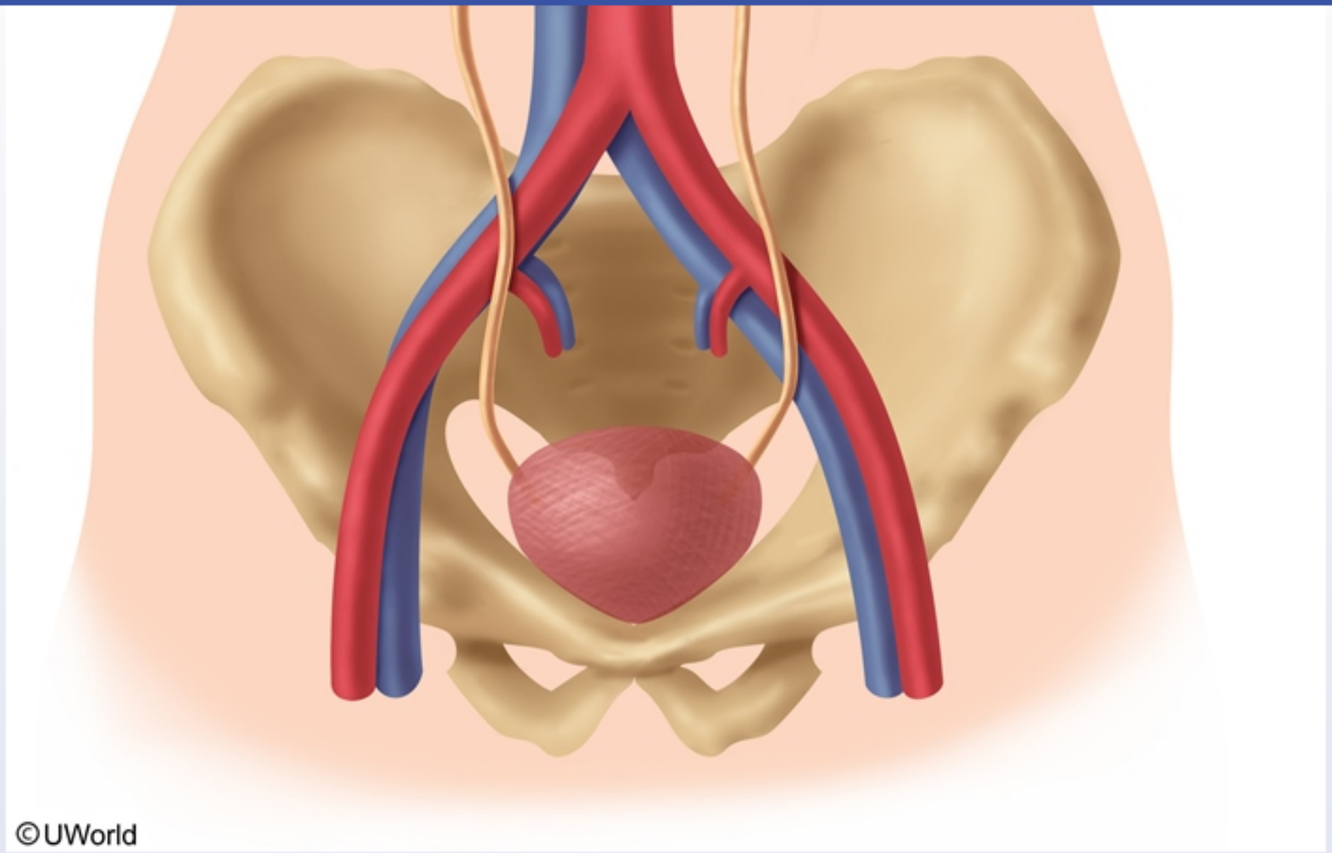

The abdominal CT scan shows the kidneys joined at their lower poles. This is the most common variant of horseshoe kidney, although fusion may also occur at the upper poles. Patients with horseshoe kidney are at increased risk of ureteropelvic junction obstruction, recurrent infection, urolithiasis, and neoplasm (Wilms tumor in children and renal cell cancer in adults). In addition, there is often an aberrant arterial supply to the horseshoe kidney with multiple accessory renal arteries.

During kidney development, the embryonic metanephros is initially located in the sacral region. The relative ascent of the kidneys to their normal anatomic position results from the disproportionately rapid growth of the caudal part of the fetus. In adults, the mature kidneys are located at vertebral levels T12-L3. When fusion of the kidneys occurs, the central isthmus of horseshoe kidney crosses the midline anterior to the aorta and posterior to the inferior mesenteric artery (IMA). During fetal development, the IMA limits ascent of the horseshoe kidney.

©UWorld

The abdominal CT scan shows the kidneys joined at their lower poles. This is the most common variant of horseshoe kidney, although fusion may also occur at the upper poles. Patients with horseshoe kidney are at increased risk of ureteropelvic junction obstruction, recurrent infection, urolithiasis, and neoplasm (Wilms tumor in children and renal cell cancer in adults). In addition, there is often an aberrant arterial supply to the horseshoe kidney with multiple accessory renal arteries.

During kidney development, the embryonic metanephros is initially located in the sacral region. The relative ascent of the kidneys to their normal anatomic position results from the disproportionately rapid growth of the caudal part of the fetus. In adults, the mature kidneys are located at vertebral levels T12-L3. When fusion of the kidneys occurs, the central isthmus of horseshoe kidney crosses the midline anterior to the aorta and posterior to the inferior mesenteric artery (IMA). During fetal development, the IMA limits ascent of the horseshoe kidney.

(Choice B) The inferior vena cava lies posterior to the isthmus of a horseshoe kidney and would not obstruct its ascent.

(Choice C) A direct connection between the bladder lumen and the outside of the body at the umbilicus is called a persistent urachus or urachal fistula. This condition would likely have been identified earlier in the patient's life.

(Choice D) The superior mesenteric artery is located above the inferior mesenteric artery. It leaves the aorta at the level of L1 and does not serve as an obstacle for the ascent of a horseshoe kidney.

(Choice E) When the vitelline duct persists, a connection is formed between the intestinal lumen and the outside of the body at the umbilicus. Discharge of meconium from the umbilicus will be seen in this condition.

Educational objective:
In horseshoe kidney, the kidneys are fused at the poles. The isthmus of the horseshoe kidney usually lies anterior to the aorta and posterior to the inferior mesenteric artery (IMA). During fetal development, the IMA limits the ascent of the horseshoe kidney.

Anatomy	Renal, Urinary Systems & Electrolytes	Congenital anomalies of kidney and urinary tract
Subject	System	Topic

Copyright © UWorld. All rights reserved.

©UWorld

Exhibit Display

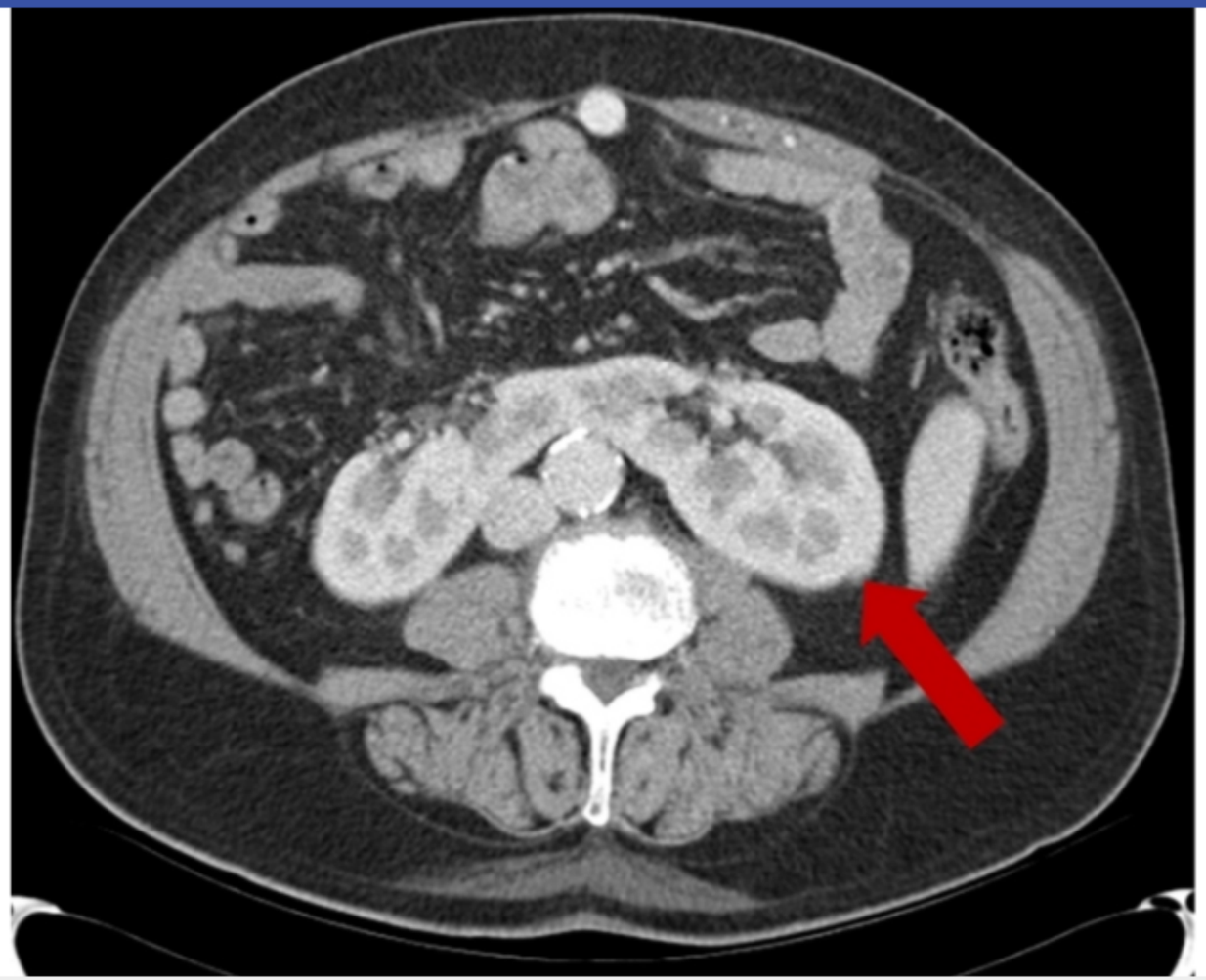

Zoom In | Zoom Out | Reset | Add To New Card | Existing Card

©UWorld

Exhibit Display

Vitelline duct abnormalities

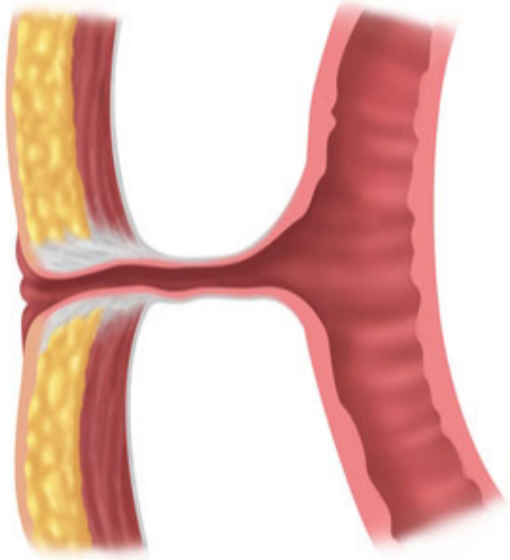

Persistent vitelline duct

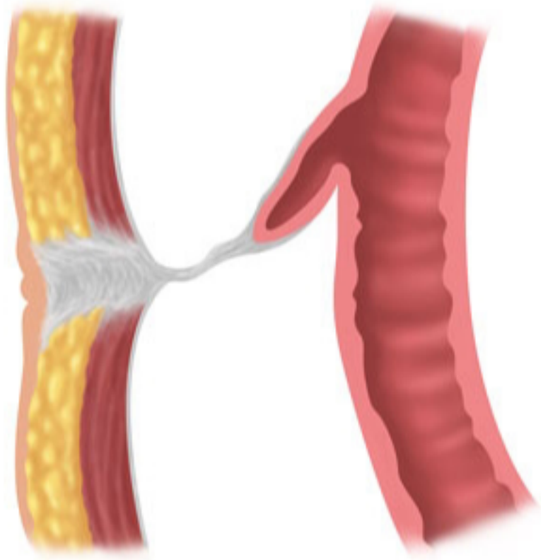

Meckel diverticulum

©UWorld

Zoom In | Zoom Out | Reset | Add To New Card | Existing Card

A 35-year-old previously healthy woman comes to the hospital due to several days of productive cough associated with chills and fever. Her sputum is purulent with faint pink streaks of blood. The patient also has sharp pain over the right shoulder and neck area brought on by deep inspiration. Past medical history is unremarkable. Her temperature is 38.3 C (101 F), blood pressure is 130/70 mm Hg, pulse is 98/min, and respirations are 22/min. Examination reveals crackles and dullness over the right lower pulmonary lobe. While listening with the stethoscope over the right midback, the examiner has the patient say the letter "E," and the sound is perceived by the examiner as a loud letter "A." A chest x-ray is obtained and is shown in the image below.

The pain experienced by this patient is most likely carried by which of the following nerves?

A. Accessory

The pain experienced by this patient is most likely carried by which of the following nerves?

- A. Accessory
- B. Intercostal
- C. Long thoracic
- D. Phrenic
- E. Vagus

Submit

The pain experienced by this patient is most likely carried by which of the following nerves?

- A. Accessory (4%)
- B. Intercostal (4%)
- C. Long thoracic (4%)
- ✓ D. Phrenic (81%)
- E. Vagus (3%)

Omitted
Correct answer

81%
Answered correctly

06 secs
Time Spent

05/31/2020
Last Updated

This patient is experiencing pleuritic chest pain due to acute lower lobe bacterial pneumonia. **Pleuritic chest pain** is characterized by sharp, localized, often severe pain that is exacerbated by coughing, breathing, or changing position. It can result from any condition that causes inflammation of the pleura (eg, infection, pulmonary embolism, uremia). The pleura are divided into segments as follows:

Visceral pleura: The visceral (pulmonary) pleura covers all surfaces of the lungs, including the surfaces within the pulmonary fissures. The visceral pleura does not carry pain fibers.

Parietal pleura: The parietal pleura forms the outer boundary of the pleural space and can be subdivided as follows:

- **Costal pleura:** Covers the thoracic wall, including the ribs, sternum, intercostal spaces, costal cartilages, and sides of the thoracic vertebrae
- **Mediastinal pleura:** Covers the mediastinum
- **Diaphragmatic pleura:** Covers the surface of the diaphragm located within the thoracic cavity
- **Cervical pleura:** Extends with the apices of the lung into the neck

The **phrenic nerve**, which is derived from the C3-C5 nerve roots, delivers motor innervation to the diaphragm and carries pain fibers from the **diaphragmatic and mediastinal pleura**. Irritation of the pleura in either area will cause a sharp pain worsened by inspiration that will be referred to the C3-C5 distribution at the base of the neck and over the shoulder. Sensory innervation of the remainder of the parietal pleura is accomplished by intercostal nerves and is typically felt closer to the source of the pain **(Choice B)**.

(Choice A) The spinal accessory nerve (cranial nerve XI) provides motor innervation to the sternocleidomastoid and trapezius muscles.

(Choice C) The long thoracic nerve innervates the serratus anterior. Damage to this nerve causes a winged scapula.

(Choice E) The vagus nerve (cranial nerve X) is the major source of parasympathetic innervation to the viscera of the chest and the foregut.

Educational objective:
Irritation of the parietal pleura will cause sharp pain, which is worse on inspiration. Pain arising from the mediastinal or diaphragmatic pleura will be carried by the phrenic nerve and referred to the C3-C5 distribution.

Anatomy Pulmonary & Critical Care Community acquired pneumonia

inflammation of the pleura (eg, infection, pulmonary embolism, uremia). The pleura are divided into segments as follows:

Visceral pleura: The visceral (pulmonary) pleura covers all surfaces of the lungs, including the surfaces within the pulmonary fissures. The visceral pleura does not carry pain fibers.

Parietal pleura: The parietal pleura forms the outer boundary of the pleural space and can be subdivided as follows:

- **Costal pleura:** Covers the thoracic wall, including the ribs, sternum, intercostal spaces, costal cartilages, and sides of the thoracic vertebrae
- **Mediastinal pleura:** Covers the mediastinum
- **Diaphragmatic pleura:** Covers the surface of the diaphragm located within the thoracic cavity
- **Cervical pleura:** Extends with the apices of the lung into the neck

The **phrenic nerve**, which is derived from the C3-C5 nerve roots, delivers motor innervation to the diaphragm and carries pain fibers from the **diaphragmatic and mediastinal pleura**. Irritation of the pleura in either area will cause a sharp pain worsened by inspiration that will be referred to the C3-C5 distribution at the base of the neck and over the shoulder. Sensory innervation of the remainder of the parietal pleura is accomplished by intercostal nerves and is typically felt closer to the source of the pain **(Choice B)**.

(Choice A) The spinal accessory nerve (cranial nerve XI) provides motor innervation to the sternocleidomastoid and trapezius muscles.

(Choice C) The long thoracic nerve innervates the serratus anterior. Damage to this nerve causes a winged scapula.

(Choice E) The vagus nerve (cranial nerve X) is the major source of parasympathetic innervation to the viscera of the chest and the foregut.

Educational objective:
Irritation of the parietal pleura will cause sharp pain, which is worse on inspiration. Pain arising from the mediastinal or diaphragmatic pleura will be carried by the phrenic nerve and referred to the C3-C5 distribution.

Anatomy	Pulmonary & Critical Care	Community acquired pneumonia
Subject	System	Topic

Copyright © UWorld. All rights reserved.

A 20-year-old man is brought to the emergency department after a motor vehicle collision. Blood pressure is 130/84 mm Hg, pulse is 108/min, and respirations are 18/min. The airway is intact, and breath and heart sounds are normal. There is bruising across the central lower abdomen and the suprapubic area is tender to palpation. Chest x-ray and pelvic x-ray reveal no fractures. Bedside ultrasound shows intraperitoneal free fluid. Urine dipstick test is positive for blood. CT scan of the abdomen and pelvis is most likely to reveal which of the following injuries in this patient?

A. Anterior bladder wall rupture

B. Bladder dome rupture

C. Bladder neck rupture

D. Renal laceration

E. Transection of anterior urethra

Submit

A 20-year-old man is brought to the emergency department after a motor vehicle collision. Blood pressure is 130/84 mm Hg, pulse is 108/min, and respirations are 18/min. The airway is intact, and breath and heart sounds are normal. There is bruising across the central lower abdomen and the suprapubic area is tender to palpation. Chest x-ray and pelvic x-ray reveal no fractures. Bedside ultrasound shows intraperitoneal free fluid. Urine dipstick test is positive for blood. CT scan of the abdomen and pelvis is most likely to reveal which of the following injuries in this patient?

- A. Anterior bladder wall rupture (23%)
- ✓ B. Bladder dome rupture (39%)
- C. Bladder neck rupture (18%)
- D. Renal laceration (3%)
- E. Transection of anterior urethra (14%)

Omitted
Correct answer
B

39%
Answered correctly

02 secs
Time Spent

01/27/2020
Last Updated

Explanation

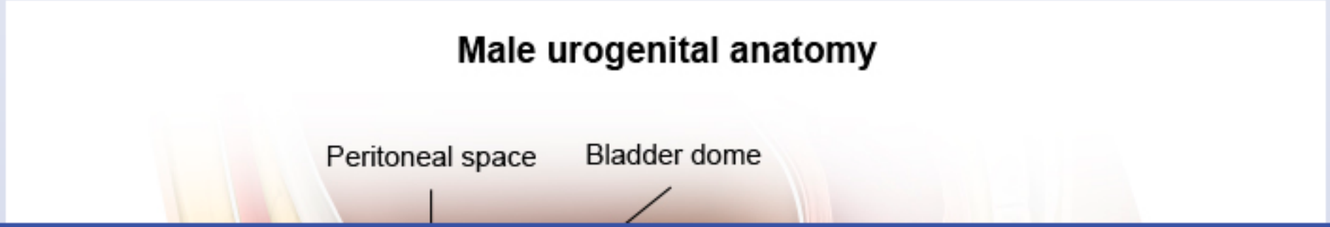

Male urogenital anatomy

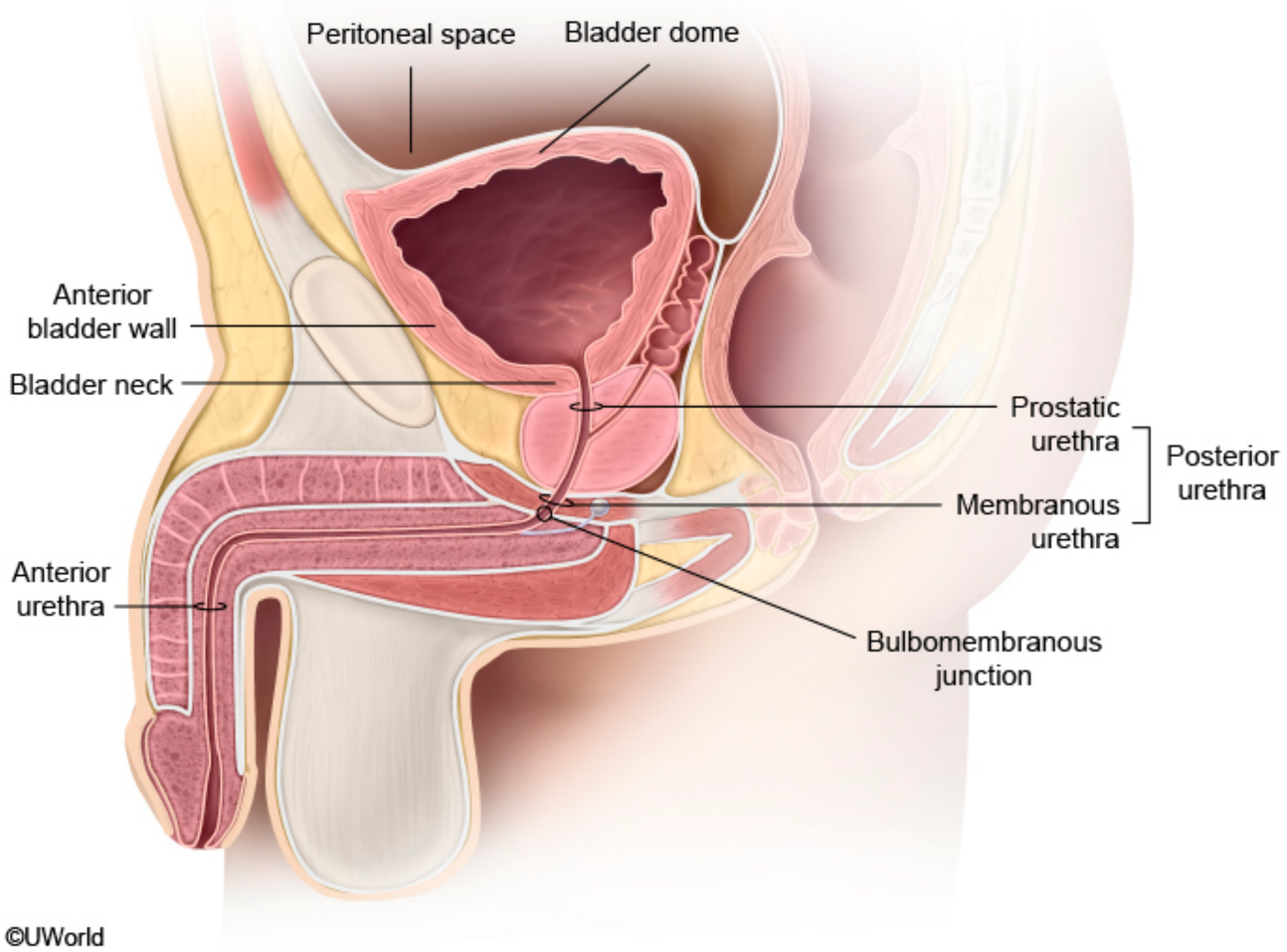

This patient's **suprapubic tenderness** and **hematuria** (ie, urine dipstick test positive for blood) in the setting of blunt trauma are concerning for a bladder injury. The additional presence of intraperitoneal free fluid (possibly urine) is further suggestive of injury to the bladder dome.

©UWorld

This patient's **suprapubic tenderness** and **hematuria** (ie, urine dipstick test positive for blood) in the setting of blunt trauma are concerning for a bladder injury. The additional presence of intraperitoneal free fluid (possibly urine) is further suggestive of injury to the bladder dome.

The bladder is a hollow pelvic organ located just posterior to the pubic symphysis. Although the bladder is extraperitoneal, the **bladder dome** is covered by peritoneal lining and **extends into the peritoneal cavity** when distended with urine. Blunt lower abdominal trauma can abruptly increase intravesicular pressure (especially when the bladder is full) and cause the bladder to **rupture** at the dome, where it is most distended and least supported by surrounding structures. As a result, urine is diverted from the urinary tract into the peritoneal cavity and can be seen on imaging as **intraperitoneal free fluid**. Peritonitis often does not develop acutely in these patients because urine is typically sterile.

(Choices A and C) The anterior bladder wall and the bladder neck are extraperitoneal structures. Therefore, a rupture in these locations would lead to extraperitoneal extravasation of urine rather than intraperitoneal leakage of urine. In addition, such ruptures are almost always accompanied by pelvic fracture.

(Choice D) The kidney is a retroperitoneal structure. Therefore, renal laceration typically causes retroperitoneal bleeding and flank pain rather than intraperitoneal free fluid and suprapubic tenderness.

(Choice E) Urethral injuries can be categorized into anterior and posterior injuries. Anterior urethral injuries are commonly caused by direct penile trauma (eg, straddle injuries, penile fracture). Posterior urethral injuries are frequently associated with pelvic fracture and may (in cases of membranous transection) cause a high-riding prostate. Although urethral injury may cause blood at the urethral meatus and/or hematuria, it does not lead to intraperitoneal free fluid because the urethra is an extraperitoneal structure.

Educational objective:
The dome of the bladder rises into the peritoneal cavity when distended with urine. Blunt lower abdominal trauma can abruptly increase intravesicular pressure and rupture the bladder dome, spilling urine into the intraperitoneal cavity.

References

- A contemporary review of adult blunt trauma.
- Blunt bladder injury.

The bladder is a hollow pelvic organ located just posterior to the pubic symphysis. Although the bladder is extraperitoneal, the **bladder dome** is covered by peritoneal lining and **extends into the peritoneal cavity** when distended with urine. Blunt lower abdominal trauma can abruptly increase intravesicular pressure (especially when the bladder is full) and cause the bladder to **rupture** at the dome, where it is most distended and least supported by surrounding structures. As a result, urine is diverted from the urinary tract into the peritoneal cavity and can be seen on imaging as **intraperitoneal free fluid**. Peritonitis often does not develop acutely in these patients because urine is typically sterile.

(Choices A and C) The anterior bladder wall and the bladder neck are extraperitoneal structures. Therefore, a rupture in these locations would lead to extraperitoneal extravasation of urine rather than intraperitoneal leakage of urine. In addition, such ruptures are almost always accompanied by pelvic fracture.

(Choice D) The kidney is a retroperitoneal structure. Therefore, renal laceration typically causes retroperitoneal bleeding and flank pain rather than intraperitoneal free fluid and suprapubic tenderness.

(Choice E) Urethral injuries can be categorized into anterior and posterior injuries. Anterior urethral injuries are commonly caused by direct penile trauma (eg, straddle injuries, penile fracture). Posterior urethral injuries are frequently associated with pelvic fracture and may (in cases of membranous transection) cause a high-riding prostate. Although urethral injury may cause blood at the urethral meatus and/or hematuria, it does not lead to intraperitoneal free fluid because the urethra is an extraperitoneal structure.

Educational objective:
The dome of the bladder rises into the peritoneal cavity when distended with urine. Blunt lower abdominal trauma can abruptly increase intravesicular pressure and rupture the bladder dome, spilling urine into the intraperitoneal cavity.

References

- A contemporary review of adult blunt trauma.
- Blunt bladder injury.

Anatomy	Renal, Urinary Systems & Electrolytes	Bladder trauma
Subject	System	Topic

Copyright © UWorld. All rights reserved.

A 32-year-old man comes to the hospital due to 1 week of progressive shortness of breath and cough. He also reports sharp right-sided chest pain that is worsened by deep inspiration. Examination reveals decreased tactile fremitus, dullness on percussion, and decreased breath sounds over the right lower lung. Chest x-ray shows consolidation of the right lower lobe and a right-sided effusion. A thoracentesis is performed, during which the needle is inserted along the upper border of the 10th rib at the right midaxillary line. Which of the following structures is most at risk of being injured as a result of the intervention?

A. Hepatic veins

B. Intercostal artery

C. Intercostal nerve

D. Right hepatic lobe

E. Right lower lung lobe

Submit

A 32-year-old man comes to the hospital due to 1 week of progressive shortness of breath and cough. He also reports sharp right-sided chest pain that is worsened by deep inspiration. Examination reveals decreased tactile fremitus, dullness on percussion, and decreased breath sounds over the right lower lung. Chest x-ray shows consolidation of the right lower lobe and a right-sided effusion. A thoracentesis is performed, during which the needle is inserted along the upper border of the 10th rib at the right midaxillary line. Which of the following structures is most at risk of being injured as a result of the intervention?

- A. Hepatic veins (1%)
- B. Intercostal artery (6%)
- C. Intercostal nerve (25%)
- ✓ D. Right hepatic lobe (44%)
- E. Right lower lung lobe (22%)

Omitted
Correct answer
D

44%
Answered correctly

02 secs
Time Spent

05/26/2020
Last Updated

Explanation

Lateral

Lateral

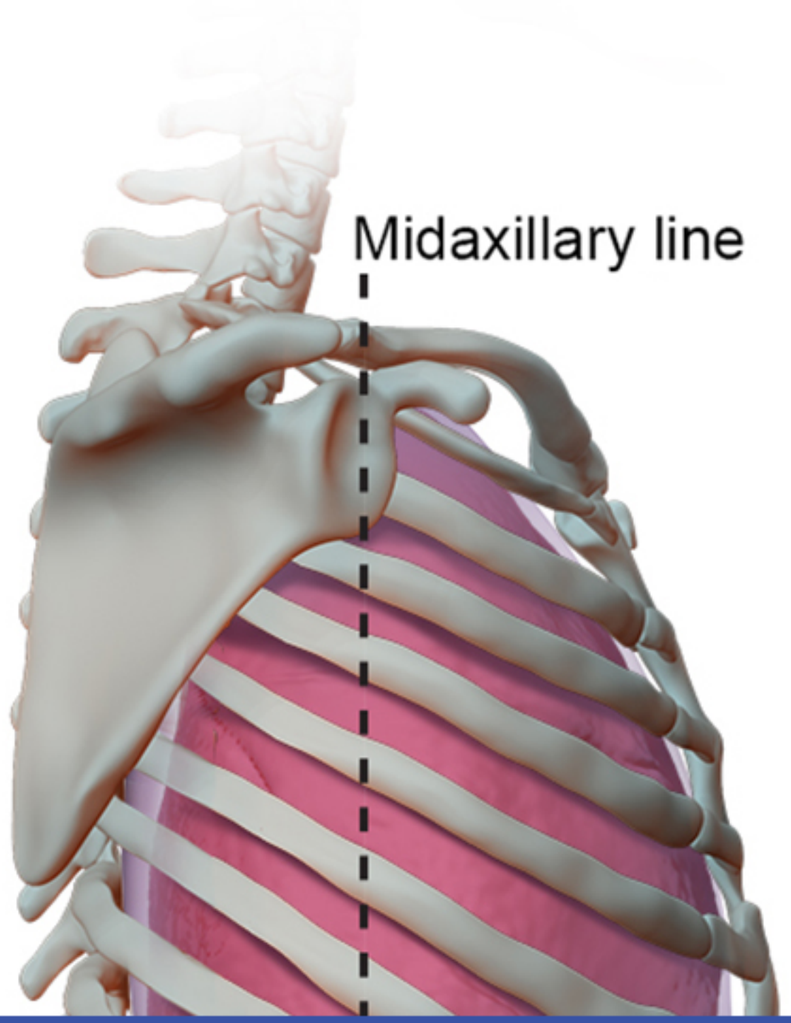

©UWorld

The visceral pleura covers the surface of the lung, whereas the parietal pleura lines the inner surface of the chest wall and diaphragm. The parietal pleura generally **extends** approximately **2 ribs below** the inferior margin of the **lungs**. The potential space at the reflection of the costal pleura onto diaphragmatic pleura is called the costodiaphragmatic recess, where pleural fluid accumulates when the body is erect.

Thoracentesis is typically performed between the 6th and 8th ribs along the midclavicular line, the 8th and 10th ribs along the midaxillary line (above image), and the 10th and 12th ribs along the paravertebral line. This allows pleural fluid to be drained without risking lung injury (which can occur at higher insertion sites). However, insertion of a needle **below the 9th** rib still **risks penetrating abdominal structures**.

In this case, thoracentesis is being performed along the **upper border of the 10th rib** at the right midaxillary line, putting the patient at risk of **liver injury** if the needle is inserted too deep.

(Choice A) Hepatic veins are found deep in the liver parenchyma and are not likely to be injured during thoracentesis.

(Choices B and C) The intercostal vein, artery, and nerve lie in the subcostal groove along the lower border of the rib. Thoracentesis should be performed just above the upper border of the rib to prevent injury to the intercostal vessels.

(Choice E) The lower border of the right lung is located 2 intercostal spaces above the pleural border. Therefore, the lung is less likely to be injured by insertion of a needle into the 10th intercostal space at the midaxillary line.

Educational objective:
Thoracentesis should be performed below the 6th rib in the midclavicular line, the 8th rib along the midaxillary line, or the 10th rib along the paravertebral line in order to minimize the risk of lung injury. Insertion of a needle lower than 9th rib increases the risk of penetrating abdominal structures. The needle should also be inserted along the upper border of the rib to prevent injury to the intercostal vessels.

Anatomy	Pulmonary & Critical Care	Thoracentesis
Subject	System	Topic

Copyright © UWorld. All rights reserved.

Exhibit Display

Topography of the lungs			
Lower border of pleura	**Midclavicular line**	**Midaxillary line**	**Paravertebral line**
Lungs (& visceral pleura)	6th rib	8th rib	10th rib
Parietal pleura	8th rib	10th rib Right - upper border Left - lower border	12th rib

©UWorld

Zoom In
Zoom Out
Reset
Add To New Card | Existing Card

Exhibit Display

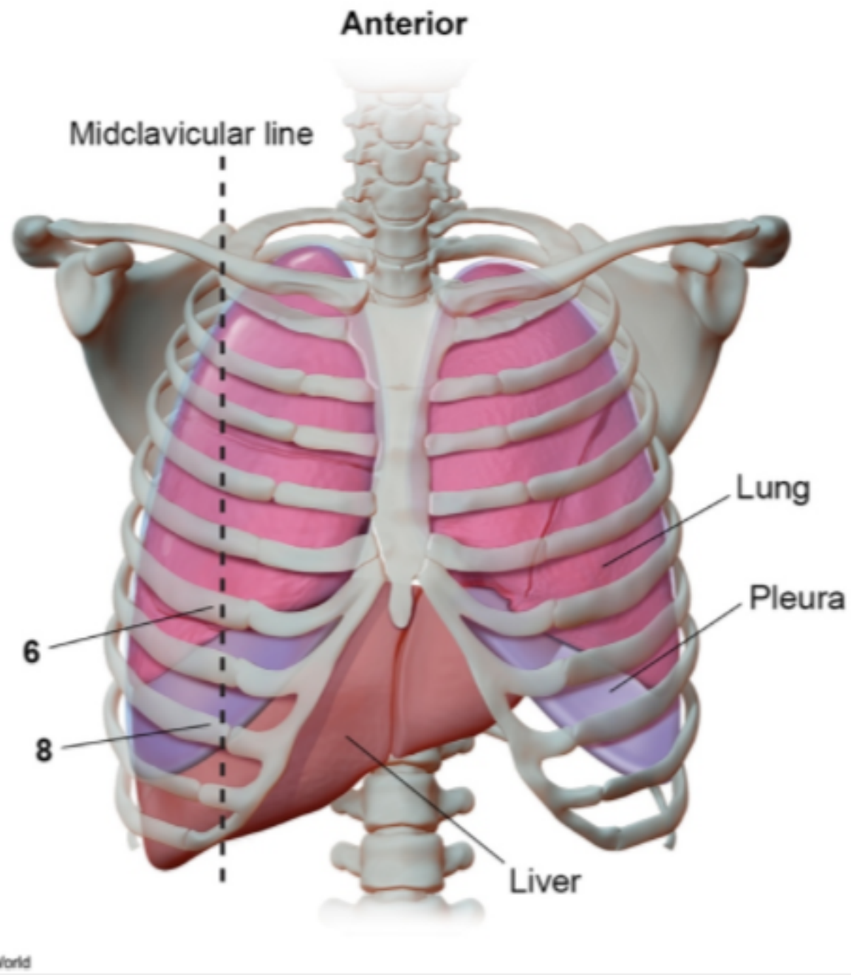

Zoom In | Zoom Out | Reset | Add To New Card | Existing Card

Exhibit Display

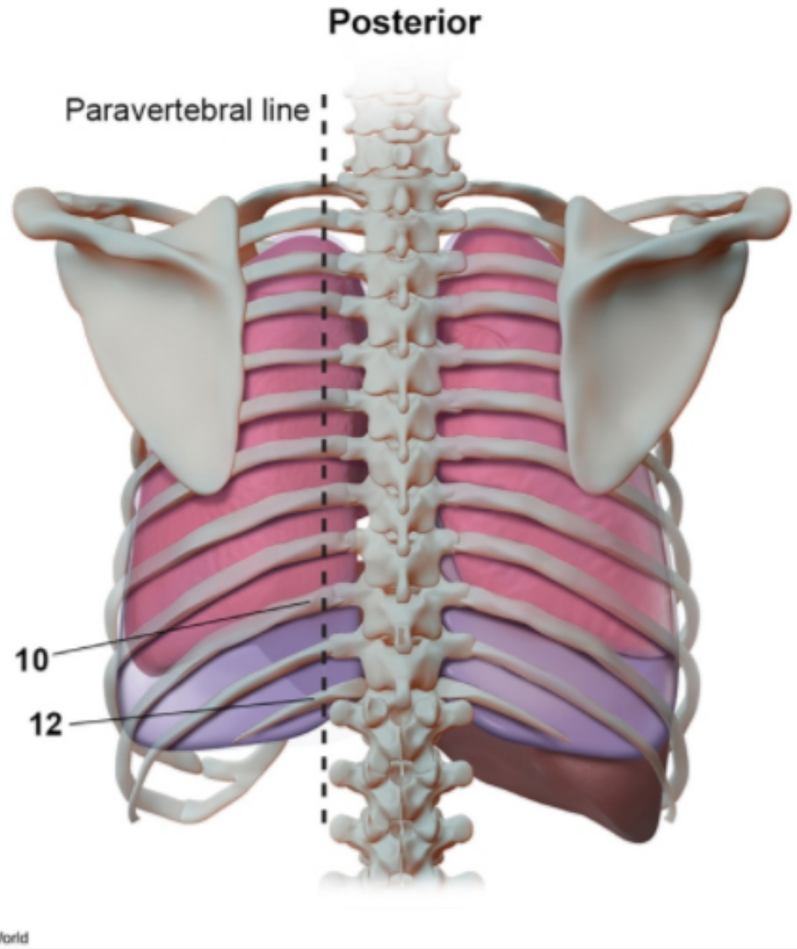

Zoom In | Zoom Out | Reset | Add To New Card | Existing Card

A 66-year-old man hospitalized 3 days ago for left lower lobe pneumonia is evaluated for persistent fever. He has been receiving the appropriate intravenous antibiotics as determined by antibiotic susceptibility testing of his sputum cultures. The patient has a history of diabetes mellitus and hypertension. His temperature is 38 C (100.4 F) and pulse is 87/min. Examination shows dullness to percussion and decreased breath sounds over the left lower lung. Imaging studies reveal a loculated, left-sided pleural effusion. A tube is placed to drain the fluid via an incision at the 5th intercostal space in the midaxillary line. Which of the following muscles is most likely to be dissected during the procedure?

A. External oblique

B. Infraspinatus

C. Latissimus dorsi

D. Pectoralis major

E. Serratus anterior

Submit

A 66-year-old man hospitalized 3 days ago for left lower lobe pneumonia is evaluated for persistent fever. He has been receiving the appropriate intravenous antibiotics as determined by antibiotic susceptibility testing of his sputum cultures. The patient has a history of diabetes mellitus and hypertension. His temperature is 38 C (100.4 F) and pulse is 87/min. Examination shows dullness to percussion and decreased breath sounds over the left lower lung. Imaging studies reveal a loculated, left-sided pleural effusion. A tube is placed to drain the fluid via an incision at the 5th intercostal space in the midaxillary line. Which of the following muscles is most likely to be dissected during the procedure?

A. External oblique (10%)

B. Infraspinatus (0%)

C. Latissimus dorsi (14%)

D. Pectoralis major (11%)

✓ E. Serratus anterior (61%)

Omitted
Correct answer
E

61%
Answered correctly

02 secs
Time Spent

04/28/2020
Last Updated

Explanation

Chest tube placement

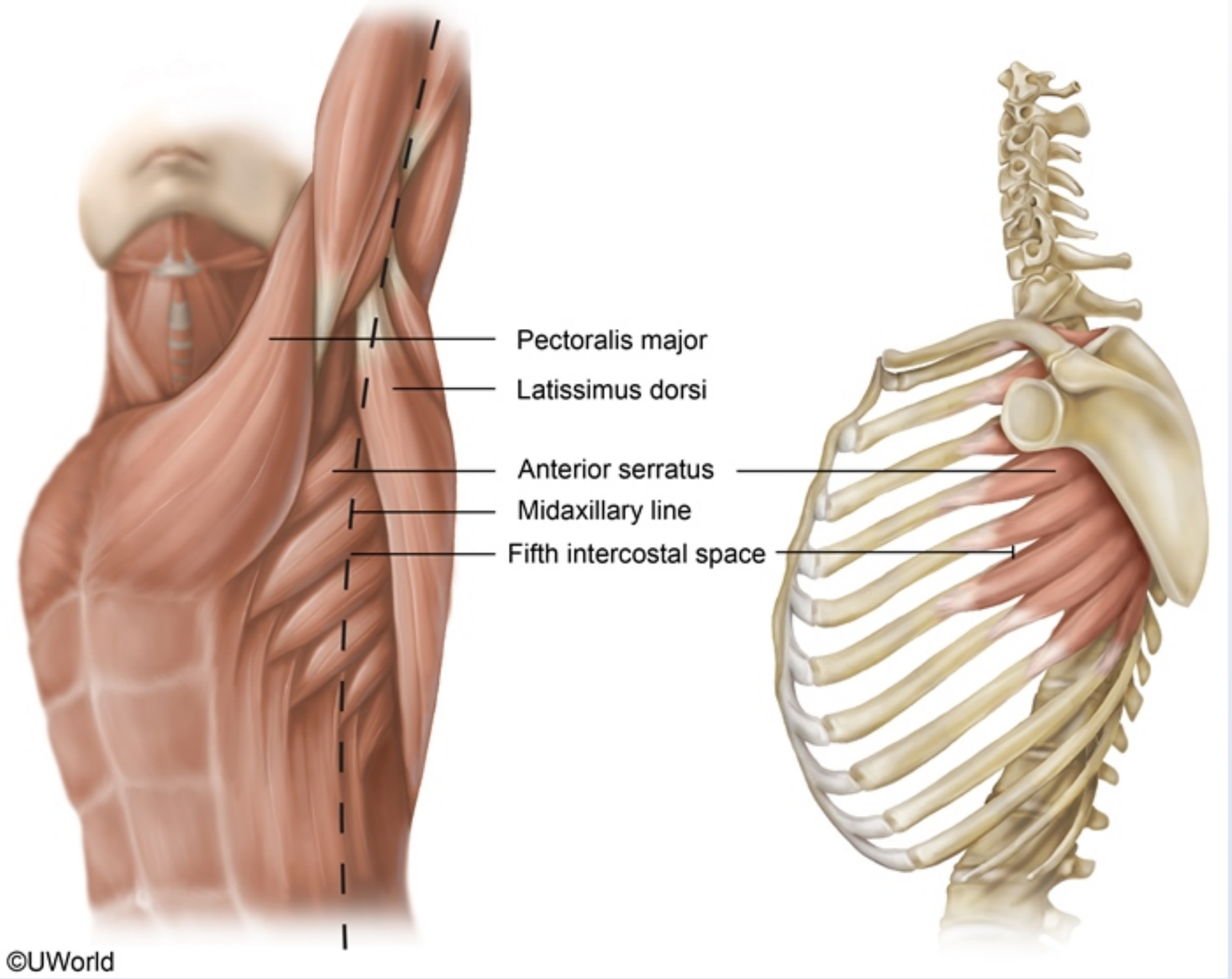

This patient most likely has empyema requiring drainage with a **chest tube**. The technique involves placing the chest tube through the skin and subcutaneous fat into the **4th or 5th intercostal space** in the anterior axillary or **midaxillary** line. The tube traverses through the **serratus**

This patient most likely has empyema requiring drainage with a **chest tube**. The technique involves placing the chest tube through the skin and subcutaneous fat into the **4th or 5th intercostal space** in the anterior axillary or **midaxillary** line. The tube traverses through the **serratus anterior** muscle, intercostal (external, internal, innermost) muscles, and parietal pleura to reach the pleural cavity.

The serratus anterior originates as multiple branches from the side of the chest along the 1st-8th ribs and inserts along the entire length of the medial scapular border. The muscle is divided into 3 parts (superior, intermediate, inferior) depending on the insertion site at the scapula. The inferior part of the muscle facilitates arm elevation by pulling the lower end of the scapula forward (scapular rotation). All 3 muscle parts can help with respiration by lifting the ribs when the shoulder girdle is fixed.

(Choice A) The external oblique originates from the lateral ribs (5-12) and extends anteriorly across the abdomen to insert into the linea alba, pubis, and iliac crest of the hip bones. The muscle is usually inferior to the chest tube insertion site.

(Choice B) The infraspinatus is a rotator cuff muscle that attaches medially to the infraspinous fossa of the scapula and laterally to the greater tubercle of the humerus. The muscle stabilizes the shoulder joint in addition to externally rotating the humerus.

(Choice C) The latissimus dorsi is a back muscle that helps with multiple shoulder movements (eg, extension, adduction). It originates from the spinous processes of T7-L5, the 9th-12th ribs, and the inferior angle of the scapula. The muscle inserts into the humerus and is located posterior to the chest tube insertion site.

(Choice D) The pectoralis major arises from the anterior clavicle, sternum, costal cartilages, and aponeurosis of the external oblique muscle. It attaches on the lateral lip of the bicipital groove of the humerus and serves to adduct and internally rotate the humerus. The muscle is anterior to the chest tube insertion site.

Educational objective:
A chest tube for drainage of pleural effusion is placed through the skin and subcutaneous fat into the 4th or 5th intercostal space in the anterior axillary or midaxillary line. The tube traverses through the serratus anterior muscle, intercostal muscles, and parietal pleura.

Anatomy	Pulmonary & Critical Care	Thoracentesis
Subject	System	Topic

Copyright © UWorld. All rights reserved.

This patient most likely has empyema requiring drainage with a **chest tube**. The technique involves placing the chest tube through the skin and

Exhibit Display

Abdominal wall musculature

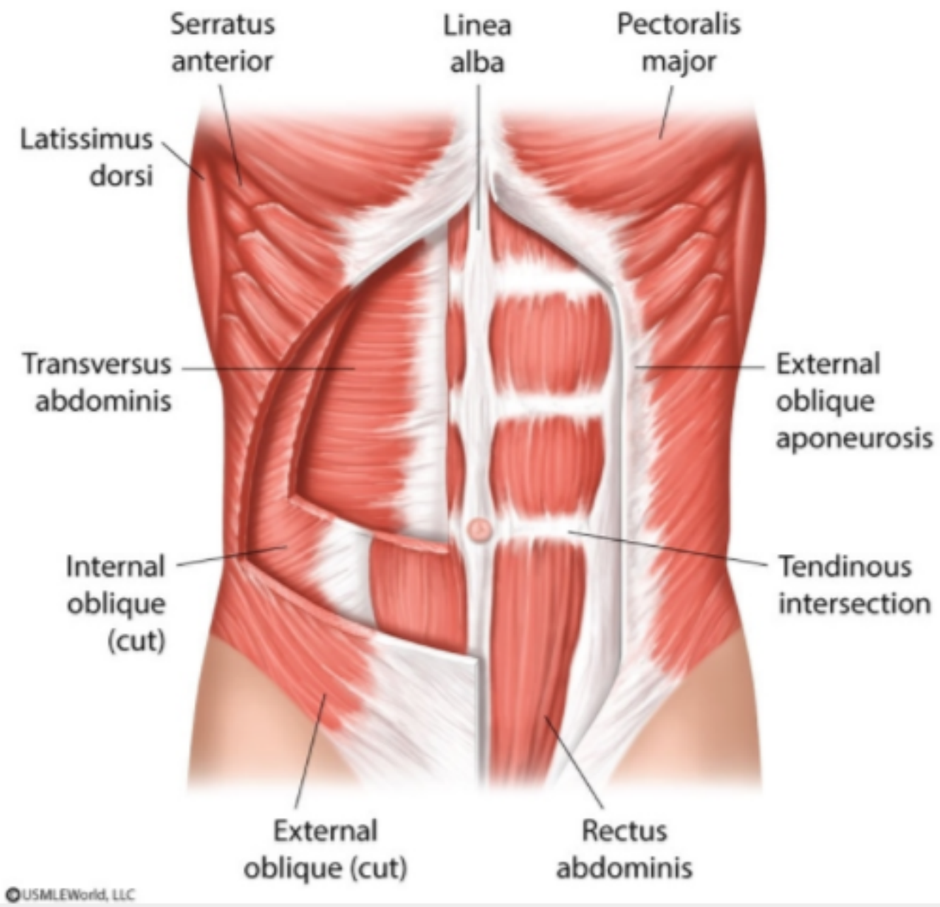

Zoom In | Zoom Out | Reset | Add To New Card | Existing Card

This patient most likely has empyema requiring drainage with a **chest tube**. The technique involves placing the chest tube through the skin and

Exhibit Display

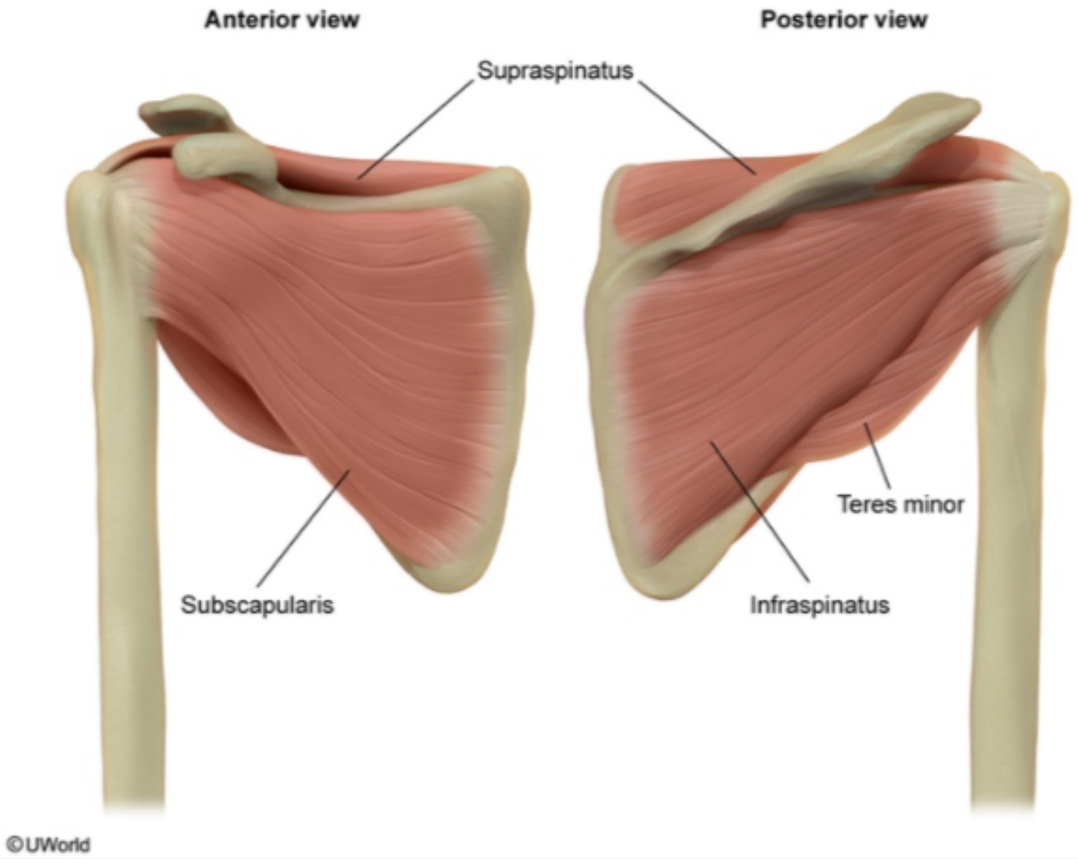

Zoom In | Zoom Out | Reset | Add To New Card | Existing Card

This patient most likely has empyema requiring drainage with a **chest tube**. The technique involves placing the chest tube through the skin and

Exhibit Display

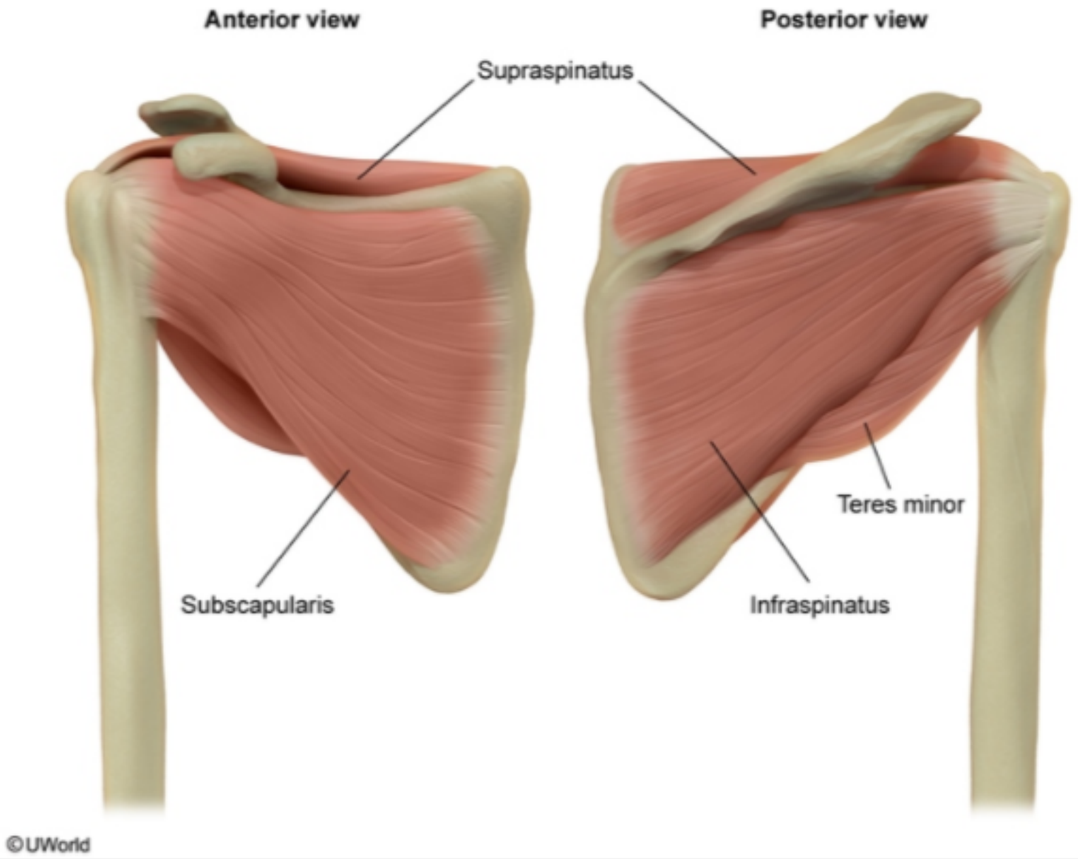

Zoom In | Zoom Out | Reset | Add To New Card | Existing Card

A 63-year-old man is admitted to the hospital after suffering a cerebral infarction. A swallow study performed during the acute recovery period shows oropharyngeal dysphagia. Despite being maintained on the appropriate dietary restrictions, the patient experiences an episode of vomiting while lying on his back and subsequently develops pneumonia. Which of the following lung regions is most likely to be affected?

A. Anterior segment of the left upper lobe

B. Basilar segments of the right lower lobe

C. Lingular segments of the left lung

D. Middle lobe segments of the right lung

E. Posterior segment of the right upper lobe

Submit

A 63-year-old man is admitted to the hospital after suffering a cerebral infarction. A swallow study performed during the acute recovery period shows oropharyngeal dysphagia. Despite being maintained on the appropriate dietary restrictions, the patient experiences an episode of vomiting while lying on his back and subsequently develops pneumonia. Which of the following lung regions is most likely to be affected?

- A. Anterior segment of the left upper lobe (0%)
- B. Basilar segments of the right lower lobe (19%)
- C. Lingular segments of the left lung (0%)
- D. Middle lobe segments of the right lung (18%)
- ✓ E. Posterior segment of the right upper lobe (60%)

Omitted
Correct answer
E

60%
Answered correctly

03 secs
Time Spent

05/04/2020
Last Updated

Explanation



Dependent lung segments

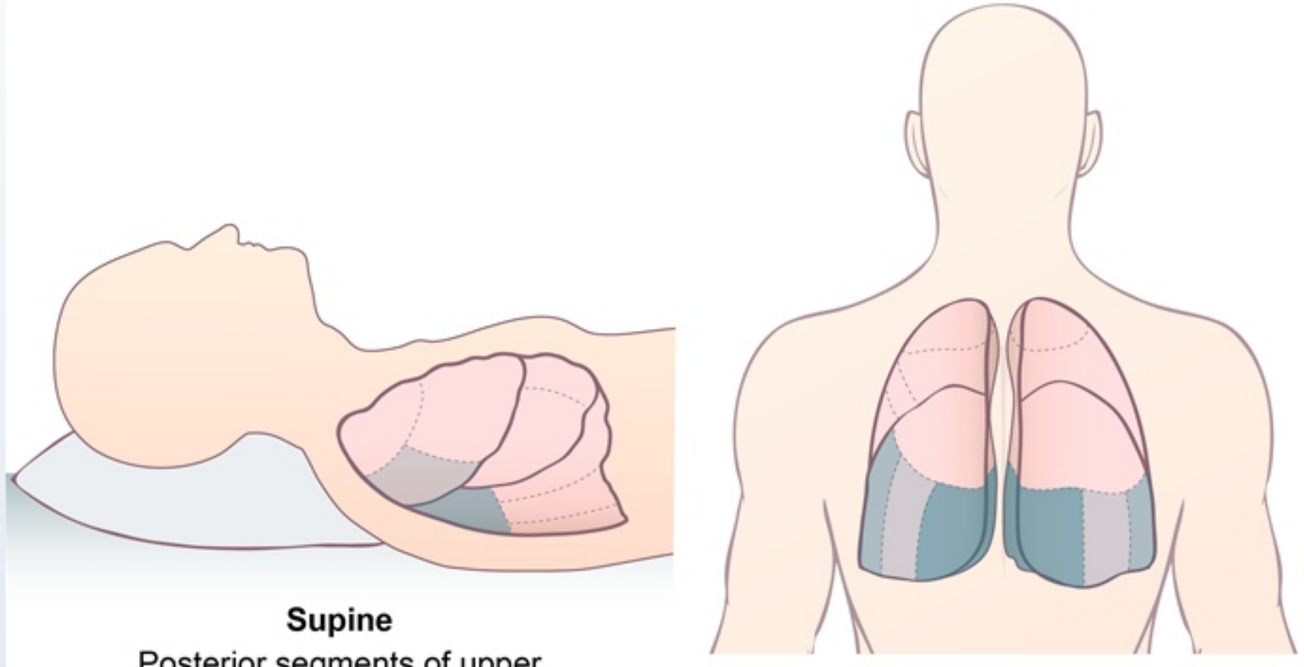

©USMLEWorld, LLC

Due to gravity, **aspiration pneumonia** typically develops in the most **dependent** portions of the lung. Patients who aspirate while **lying supine** typically have involvement of the **posterior segments of the upper lobes** and the **superior segments of the lower lobes**.

The **right lung** is more prone to aspiration than the left lung as the right main bronchus has a larger diameter, is shorter, and is more vertically oriented than the left main bronchus (mnemonic: "Inhale a bite, goes down the right").

(Choice B) Aspiration in an upright position tends to involve the basilar segments of the lower lobes.

(Choices C and D) Recumbent patients in the *prone position* (ie, lying on the abdomen) are more likely to aspirate into the middle lobe and lingula, as these are the most dependent portions of the lung in this position.

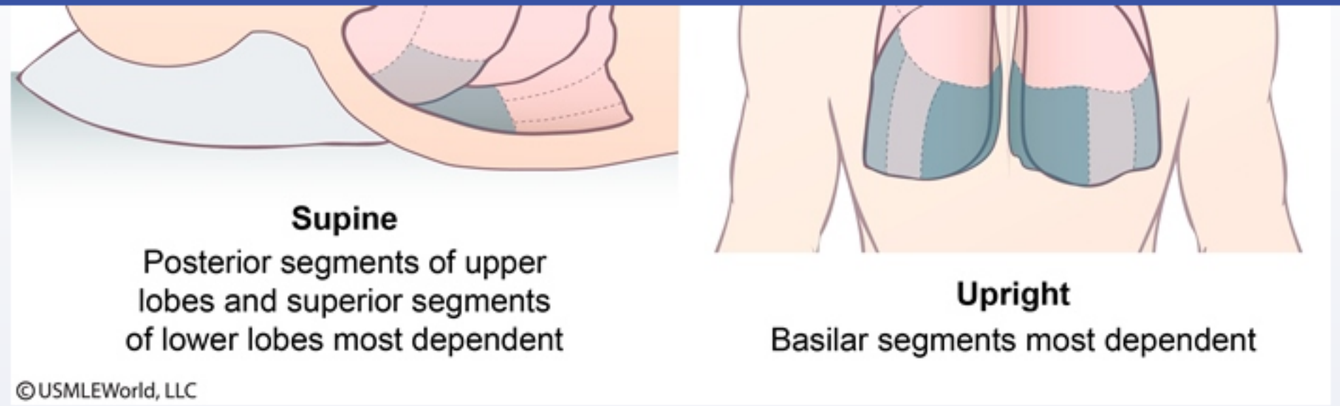

Due to gravity, **aspiration pneumonia** typically develops in the most **dependent** portions of the lung. Patients who aspirate while **lying supine** typically have involvement of the **posterior segments of the upper lobes** and the **superior segments of the lower lobes**.

The **right lung** is more prone to aspiration than the left lung as the right main bronchus has a larger diameter, is shorter, and is more vertically oriented than the left main bronchus (mnemonic: "Inhale a bite, goes down the right").

(Choice B) Aspiration in an upright position tends to involve the basilar segments of the lower lobes.

(Choices C and D) Recumbent patients in the *prone position* (ie, lying on the abdomen) are more likely to aspirate into the middle lobe and lingula, as these are the most dependent portions of the lung in this position.

Educational objective:
Due to gravity, supine patients typically aspirate into the posterior segments of the upper lobes and superior segments of the lower lobes. Patients who are upright tend to aspirate into the basilar segments of the lower lobes. Aspirated material is more likely to travel down the right main bronchus.

Anatomy	Pulmonary & Critical Care	Aspiration pneumonia
Subject	System	Topic

Copyright © UWorld. All rights reserved.

A 57-year-old man comes to the office due to unrefreshing sleep. He feels tired during the day and occasionally has to nap during his lunch hours. According to his wife, the patient snores loudly during sleep and frequently gasps for breath. He also has severe claustrophobia. Past medical history is significant for hypertension. The patient takes no sedative medications and is a lifetime nonsmoker. Blood pressure is 156/94 mm Hg and BMI is 30 kg/m^2. Physical examination is significant for a bulky tongue and crowded, narrow oropharynx. Electrical stimulation of which of the following nerves may improve the pathophysiologic cause of this patient's symptoms?

A. Hypoglossal
B. Lingual
C. Maxillary
D. Phrenic
E. Recurrent laryngeal

Submit

A 57-year-old man comes to the office due to unrefreshing sleep. He feels tired during the day and occasionally has to nap during his lunch hours. According to his wife, the patient snores loudly during sleep and frequently gasps for breath. He also has severe claustrophobia. Past medical history is significant for hypertension. The patient takes no sedative medications and is a lifetime nonsmoker. Blood pressure is 156/94 mm Hg and BMI is 30 kg/m^2. Physical examination is significant for a bulky tongue and crowded, narrow oropharynx. Electrical stimulation of which of the following nerves may improve the pathophysiologic cause of this patient's symptoms?

- ✓ A. Hypoglossal (57%)
- B. Lingual (4%)
- C. Maxillary (2%)
- D. Phrenic (16%)
- E. Recurrent laryngeal (18%)

Omitted
Correct answer
A

57%
Answered correctly

02 secs
Time Spent

06/29/2020
Last Updated

Explanation

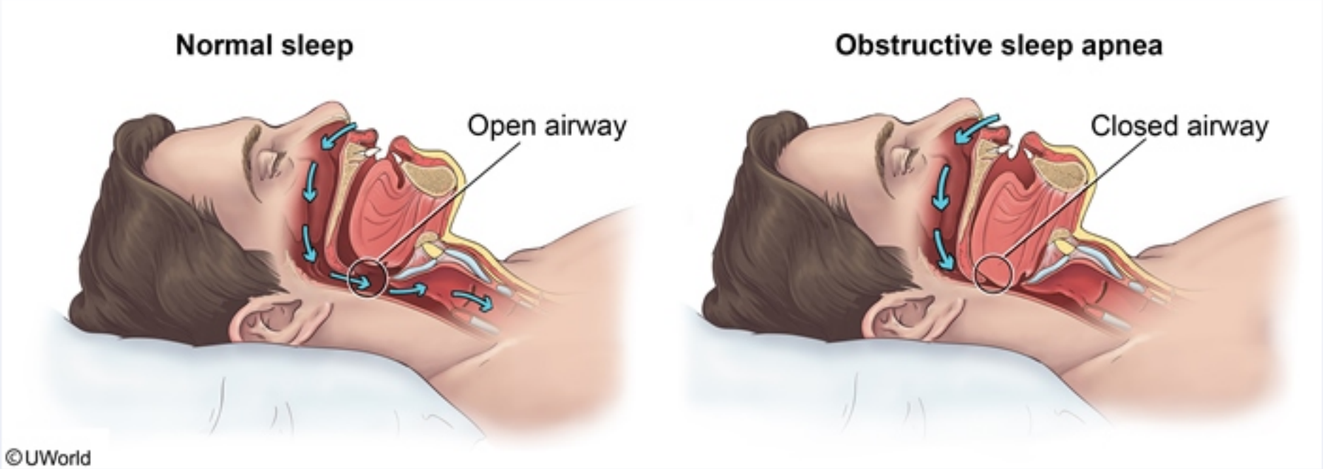

Obstructive sleep apnea (OSA) is characterized by recurrent episodes of **upper airway collapse** during sleep. Anatomical and neuromuscular mechanisms have been implicated in OSA. **Neuromuscular weakness** as a pathogenic mechanism in OSA is supported by the fact that apneas occur only during sleep, a time of muscle relaxation. The upper airway dilator muscles weaken during the transition from wake to sleep, leading to airway narrowing and ultimately collapse in individuals with OSA.

Stimulation of the **hypoglossal nerve** using an implantable nerve stimulator causes the tongue to move forward slightly, increasing the anteroposterior diameter of the airway. Studies with these devices have shown a reduction in the number of obstructive events during sleep.

(Choices B and C) The lingual nerve arises from the mandibular division of the trigeminal nerve and supplies sensory innervation to the tongue. The maxillary division of the trigeminal nerve provides sensation to the mid-face area. Neither of these nerves provides motor innervation to the oropharyngeal muscles involved in OSA.

(Choice D) The phrenic nerve supplies the diaphragm. Although diaphragmatic paralysis can cause sleep apnea, OSA with loud snoring and gasping respirations is due to oropharyngeal rather than diaphragmatic dysfunction.

(Choice E) The vocal cords are innervated by the recurrent laryngeal nerve, but sleep apnea is primarily a problem of the pharynx, not larynx.

Educational objective:

Obstructive sleep apnea (OSA) is characterized by recurrent episodes of **upper airway collapse** during sleep. Anatomical and neuromuscular mechanisms have been implicated in OSA. **Neuromuscular weakness** as a pathogenic mechanism in OSA is supported by the fact that apneas occur only during sleep, a time of muscle relaxation. The upper airway dilator muscles weaken during the transition from wake to sleep, leading to airway narrowing and ultimately collapse in individuals with OSA.

Stimulation of the **hypoglossal nerve** using an implantable nerve stimulator causes the tongue to move forward slightly, increasing the anteroposterior diameter of the airway. Studies with these devices have shown a reduction in the number of obstructive events during sleep.

(Choices B and C) The lingual nerve arises from the mandibular division of the trigeminal nerve and supplies sensory innervation to the tongue. The maxillary division of the trigeminal nerve provides sensation to the mid-face area. Neither of these nerves provides motor innervation to the oropharyngeal muscles involved in OSA.

(Choice D) The phrenic nerve supplies the diaphragm. Although diaphragmatic paralysis can cause sleep apnea, OSA with loud snoring and gasping respirations is due to oropharyngeal rather than diaphragmatic dysfunction.

(Choice E) The vocal cords are innervated by the recurrent laryngeal nerve, but sleep apnea is primarily a problem of the pharynx, not larynx.

Educational objective:
Neuromuscular weakness of the oropharynx is involved in the pathophysiology of obstructive sleep apnea. Electrical stimulation of the hypoglossal nerve increases the diameter of the oropharyngeal airway and decreases the frequency of apneic events.

References

- Hypoglossal nerve stimulation for obstructive sleep apnea.

Anatomy	Pulmonary & Critical Care	Obstructive sleep apnea
Subject	System	Topic

Copyright © UWorld. All rights reserved.

A 45-year-old man with a history of end-stage renal disease undergoes renal allograft transplantation. The donor kidney and proximal ureter are transplanted in the right iliac fossa, with implantation of the ureter into the patient's bladder. Six days following surgery, the donor kidney appears to be functioning well, but the patient develops fever and right lower quadrant abdominal pain. Imaging studies reveal a large pelvic fluid collection. Exploratory laparotomy is performed and discovers urinary leakage, with significant ischemia and necrosis of the transplanted ureter immediately adjacent to the site of implantation into the bladder. The proximal portion of the ureter appears normal. The healthy segment of this patient's transplanted ureter is most likely receiving blood from which of the following arteries?

- A. Common iliac artery
- B. Internal iliac artery
- C. Lumbar arteries
- D. Phrenic artery
- E. Renal artery
- F. Superior vesical artery

Submit

A 45-year-old man with a history of end-stage renal disease undergoes renal allograft transplantation. The donor kidney and proximal ureter are transplanted in the right iliac fossa, with implantation of the ureter into the patient's bladder. Six days following surgery, the donor kidney appears to be functioning well, but the patient develops fever and right lower quadrant abdominal pain. Imaging studies reveal a large pelvic fluid collection. Exploratory laparotomy is performed and discovers urinary leakage, with significant ischemia and necrosis of the transplanted ureter immediately adjacent to the site of implantation into the bladder. The proximal portion of the ureter appears normal. The healthy segment of this patient's transplanted ureter is most likely receiving blood from which of the following arteries?

- A. Common iliac artery (12%)
- B. Internal iliac artery (22%)
- C. Lumbar arteries (4%)
- D. Phrenic artery (0%)
- ✓ E. Renal artery (50%)
- F. Superior vesical artery (10%)

Omitted
Correct answer
E

50%
Answered correctly

02 secs
Time Spent

04/25/2020
Last Updated

Explanation

Ureteral circulation

Ureteral circulation

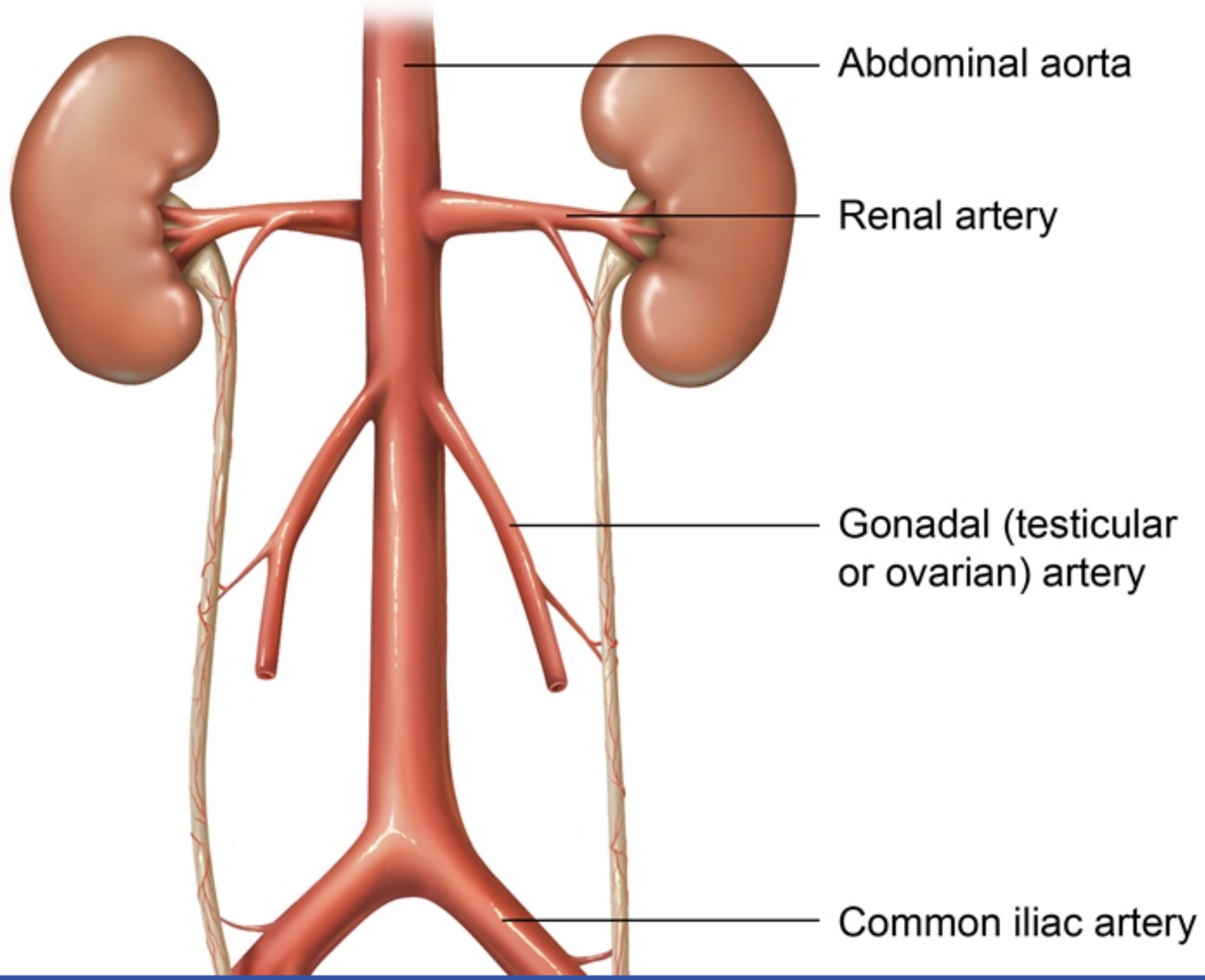

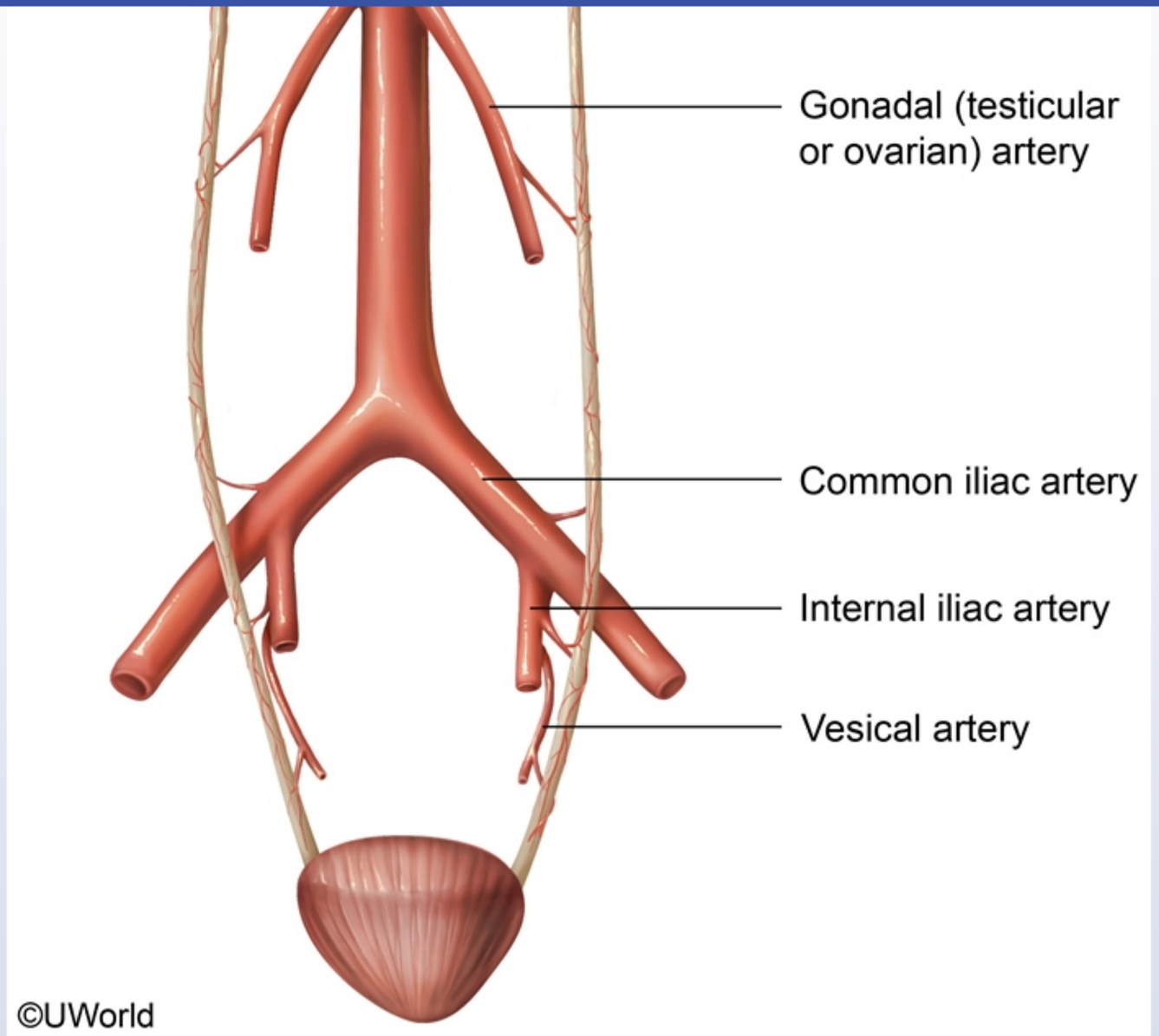
Gonadal (testicular or ovarian) artery
Common iliac artery
Internal iliac artery
Vesical artery
©UWorld

The blood supply to the **proximal ureter** comes from branches of the **renal artery**. At the distal ureter, arterial blood supply arises from the superior vesical artery. In between, the arterial supply to the ureter is anastomotic and highly variable, with possible afferent branches from the gonadal, common and internal iliac, aorta, and uterine arteries.

In a kidney transplant operation, the native kidneys are typically left in place, and the donor kidney is placed retroperitoneally in the right iliac fossa. Blood supply is established by **anastomosing** the **donor renal artery** with the recipient's **external iliac artery**. The proximal 1/3 of the donor ureter is preserved and used to establish continuity from the collecting system of the kidney to the recipient's bladder. Although the transplanted ureter will continue to receive blood through the donor's renal artery, the most distal portion may be susceptible to ischemia due to lack of anastomotic connections. **Distal ureteral ischemia** is a recognized complication of renal transplant and causes leakage of urine 5-10 days following transplant.

(Choices A, B, and F) Branches from the common iliac, internal iliac, and superior vesical arteries supply more distal segments of the ureter, which are not typically retained in the transplanted specimen in order to limit distal ureteral ischemia.

(Choice C) The lumbar arteries arise directly from the aorta to supply the lumbar vertebrae and surrounding structures.

(Choice D) The inferior phrenic arteries are branches of the aorta that supply the diaphragm and provide branches to the suprarenal glands.

Educational objective:
The proximal ureter receives its blood supply from the renal artery whereas the distal ureter is supplied by the superior vesical artery. Circulation to the middle portions of the ureter is variable and anastomotic.

Anatomy	Renal, Urinary Systems & Electrolytes	Ureter injury
Subject	System	Topic

Copyright © UWorld. All rights reserved.

A 13-year-old girl is admitted for fever, cough, and malaise for the past two days. She has no history of sick contacts and all her immunizations are up to date. Her leukocyte count is 21,000/mm^3 with 7% band forms. Upright chest x-ray findings are shown in the image below:

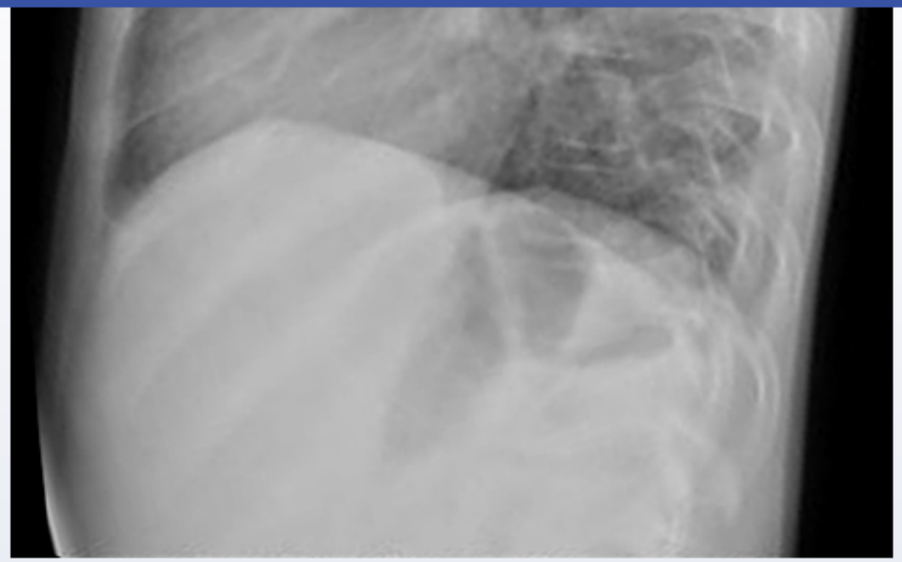

Which of the following is the most likely location of the pathologic process in this patient?

- A. Left lower lung lobe
- B. Left pleural space
- C. Left upper lung lobe
- D. Right middle lung lobe
- E. Right pleural space
- F. Right upper lung lobe

Submit

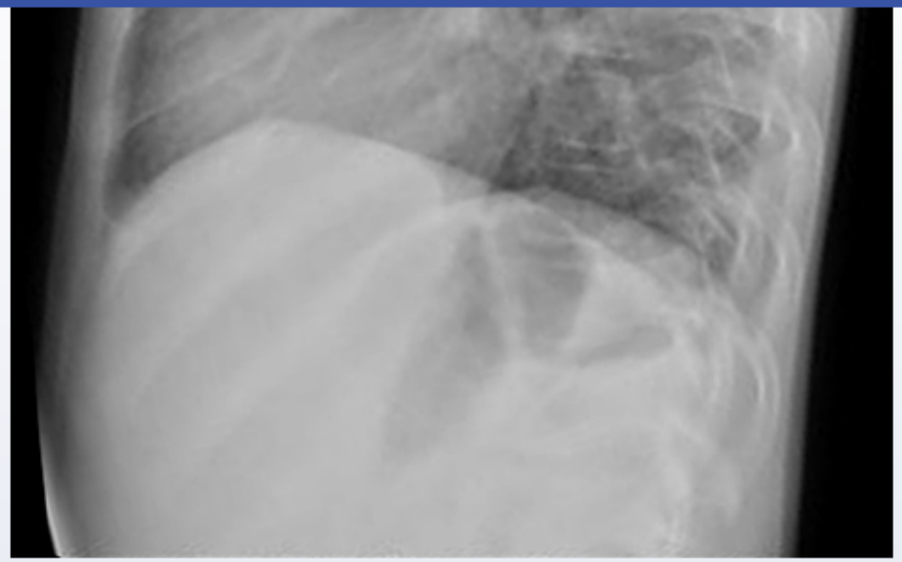

Which of the following is the most likely location of the pathologic process in this patient?

A. Left lower lung lobe (8%)

B. Left pleural space (4%)

C. Left upper lung lobe (34%)

D. Right middle lung lobe (27%)

E. Right pleural space (1%)

✓ F. Right upper lung lobe (23%)

Omitted
Correct answer

23%
Answered correctly

05 secs
Time Spent

03/25/2020
Last Updated

F

Explanation

Right upper lobe pneumonia

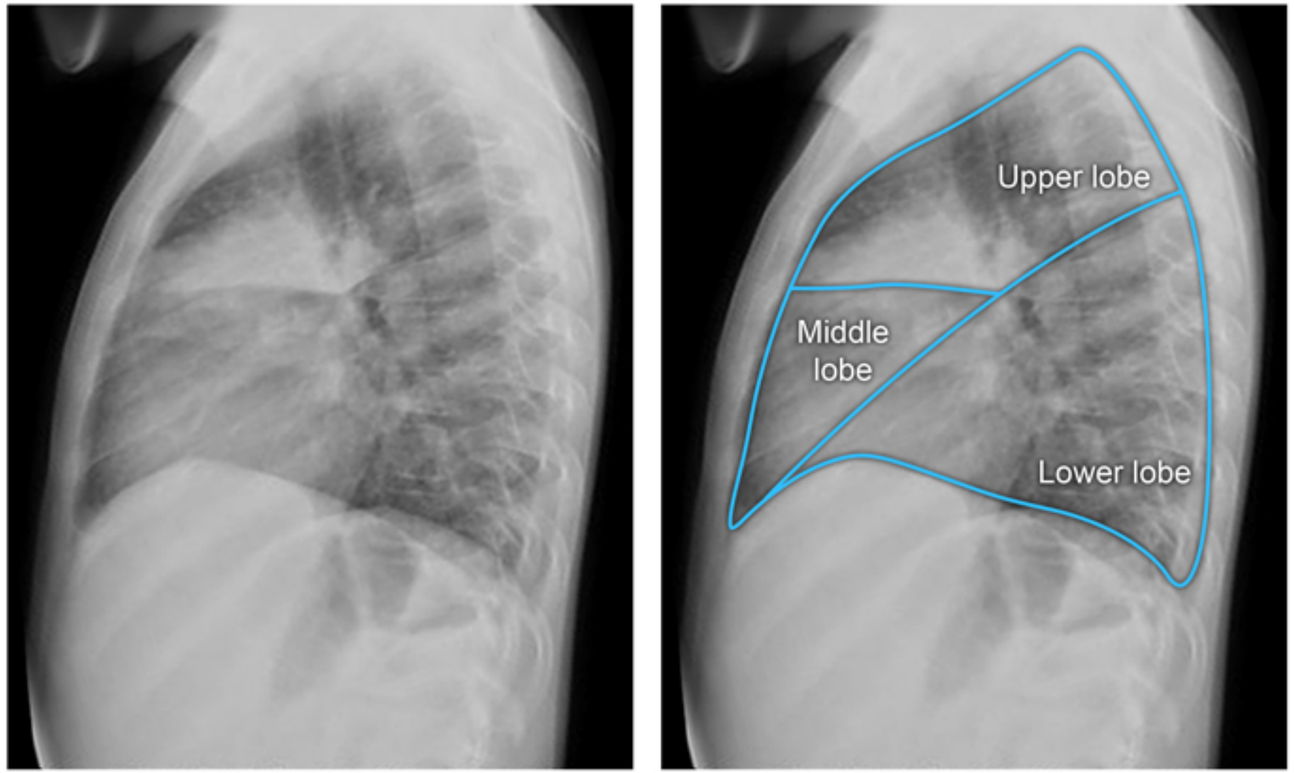

©UWorld

This patient has fever, productive cough, leukocytosis with left shift, and an area of **consolidation** on chest x-ray consistent with lobar **pneumonia**. Pulmonary consolidation occurs when the air in alveoli is replaced with a substance (eg, edema, pus, blood, cellular debris) that

This patient has fever, productive cough, leukocytosis with left shift, and an area of **consolidation** on chest x-ray consistent with lobar **pneumonia**. Pulmonary consolidation occurs when the air in alveoli is replaced with a substance (eg, edema, pus, blood, cellular debris) that results in a region of **opacification** on radiographs. If the consolidation surrounds bronchi, the air in the bronchi can be more apparent against the opacity (ie, air bronchogram).

Lobar consolidation typically begins in the lung periphery, which has the highest concentration of alveoli, and it can spread from one alveolus to another (even between adjacent lobules of the same lobe) through specialized connections (eg, pores of Kohn). The borders of a consolidation tend to be indistinct as the alveoli become more sporadically involved at the peripheral portions of the disease process. However, if the consolidation abuts a fissure (eg, oblique, horizontal), there can be a **sharper delineation** because the consolidation cannot directly spread across the fissure to another lobe.

This patient has a consolidation with a sharp delineation **inferiorly at the horizontal fissure**, which separates the right upper lobe from the right middle lobe. This finding is consistent with right upper lobe pneumonia.

(Choices A and C) Left lower lobe pneumonia and left upper lobe pneumonia can have a diagonal delineation at the oblique fissure but would not have a horizontal delineation, as there is no middle lobe on the left side.

(Choice D) Pneumonia involving the right middle lobe would typically be visualized as a consolidation over the heart that may have a sharp delineation above (horizontal fissure) and/or below (oblique fissure).

(Choices B and E) In an upright chest x-ray, large accumulations of fluid in the pleural space (eg, pleural effusion) can blunt the costophrenic angles and spread across lung fissures to involve the area around more than one lung lobe.

Educational objective:
Pulmonary consolidation is caused by accumulation of material (eg, fluid, cellular debris) in the alveoli, which can be visualized on radiographs as an area of opacification with indistinct borders. A sharp horizontal or oblique delineation indicates that the consolidation abuts one of the lung fissures. Consolidation with a sharp delineation inferiorly at the horizontal fissure is consistent with right upper lobe pneumonia.

Anatomy	Pulmonary & Critical Care	Lung segments
Subject	System	Topic

pneumonia. Pulmonary consolidation occurs when the air in alveoli is replaced with a substance (eg, edema, pus, blood, cellular debris) that results in a region of **opacification** on radiographs. If the consolidation surrounds bronchi, the air in the bronchi can be more apparent against the opacity (ie, air bronchogram).

Lobar consolidation typically begins in the lung periphery, which has the highest concentration of alveoli, and it can spread from one alveolus to another (even between adjacent lobules of the same lobe) through specialized connections (eg, pores of Kohn). The borders of a consolidation tend to be indistinct as the alveoli become more sporadically involved at the peripheral portions of the disease process. However, if the consolidation abuts a fissure (eg, oblique, horizontal), there can be a **sharper delineation** because the consolidation cannot directly spread across the fissure to another lobe.

This patient has a consolidation with a sharp delineation **inferiorly at the horizontal fissure**, which separates the right upper lobe from the right middle lobe. This finding is consistent with right upper lobe pneumonia.

(Choices A and C) Left lower lobe pneumonia and left upper lobe pneumonia can have a diagonal delineation at the oblique fissure but would not have a horizontal delineation, as there is no middle lobe on the left side.

(Choice D) Pneumonia involving the right middle lobe would typically be visualized as a consolidation over the heart that may have a sharp delineation above (horizontal fissure) and/or below (oblique fissure).

(Choices B and E) In an upright chest x-ray, large accumulations of fluid in the pleural space (eg, pleural effusion) can blunt the costophrenic angles and spread across lung fissures to involve the area around more than one lung lobe.

Educational objective:
Pulmonary consolidation is caused by accumulation of material (eg, fluid, cellular debris) in the alveoli, which can be visualized on radiographs as an area of opacification with indistinct borders. A sharp horizontal or oblique delineation indicates that the consolidation abuts one of the lung fissures. Consolidation with a sharp delineation inferiorly at the horizontal fissure is consistent with right upper lobe pneumonia.

Anatomy	Pulmonary & Critical Care	Lung segments
Subject	System	Topic

Copyright © UWorld. All rights reserved.

1
2
3
4
5
6
7
8
9
10
11
12
13
14
15

pneumonia. Pulmonary consolidation occurs when the air in alveoli is replaced with a substance (eg, edema, pus, blood, cellular debris) that results in a region o
opacity (ie, air bronc

Lobar consolidatio
another (even betwe
tend to be indistinct
consolidation abuts
across the fissure to

This patient has a c
middle lobe. This fi

(Choices A and C)
have a horizontal de

(Choice D) Pneum
delineation above (h

(Choices B and E)
angles and spread a

Educational object
Pulmonary consolid
an area of opacifica
fissures. Consolida

Anatomy
Subject

Pul
Sys

Exhibit Display

Air bronchogram

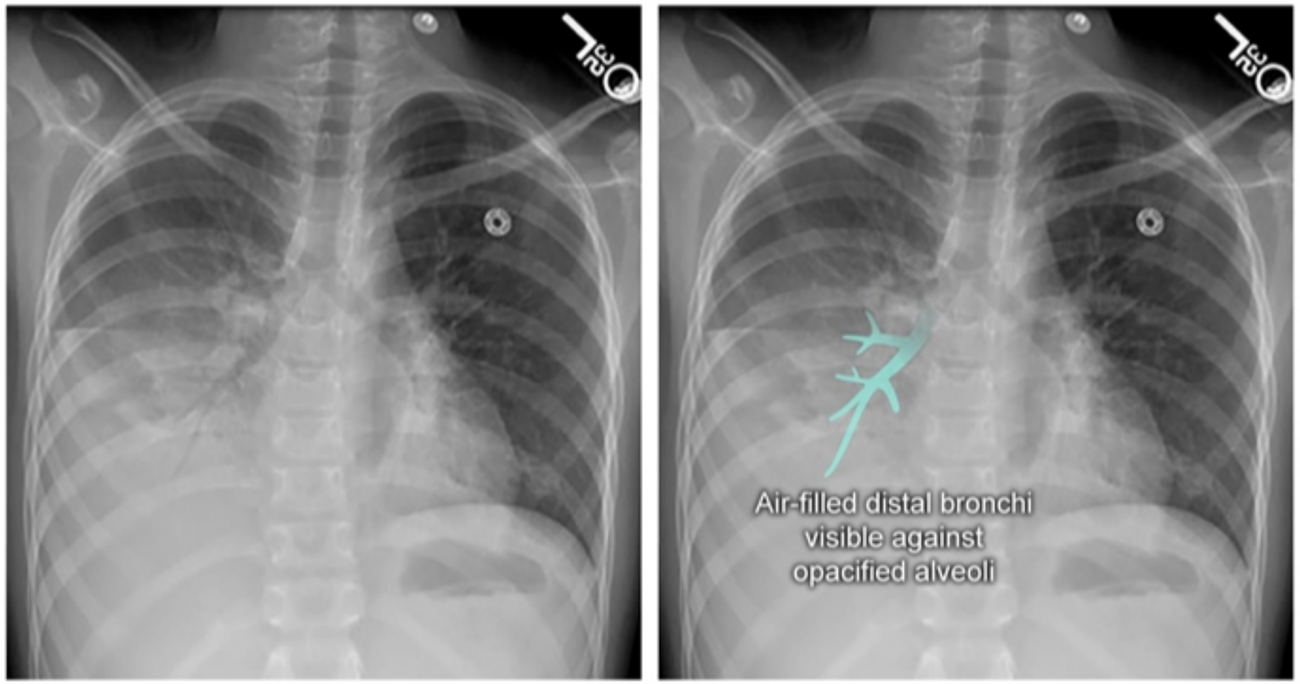

©UWorld

Zoom In
Zoom Out
Reset
Add To Flash Card

pneumonia. Pulmonary consolidation occurs when the air in alveoli is replaced with a substance (eg, edema, pus, blood, cellular debris) that

Exhibit Display

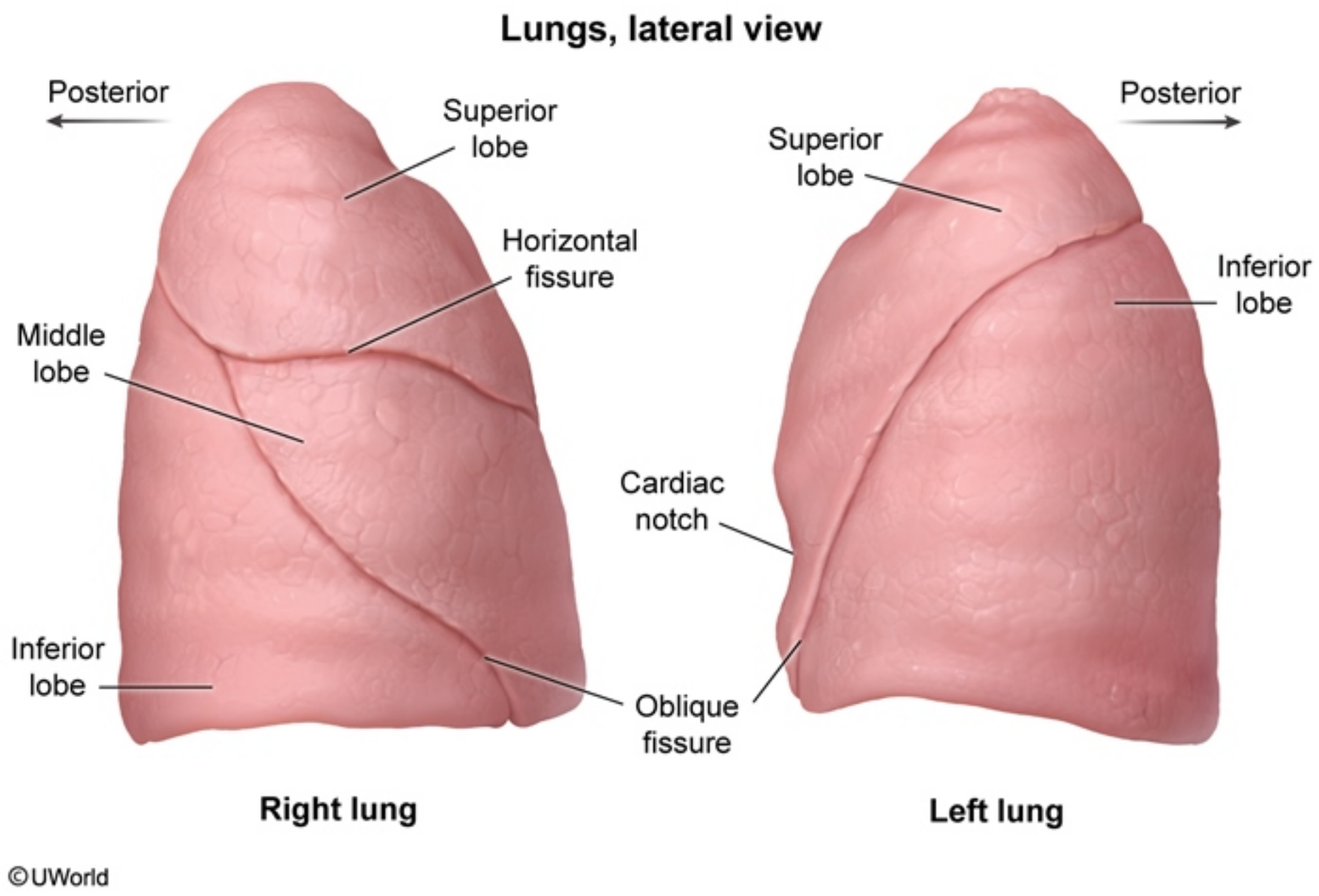

Zoom In
Zoom Out
Reset
Add To Flash Card

pneumonia. Pulmonary consolidation occurs when the air in alveoli is replaced with a substance (eg, edema, pus, blood, cellular debris) that

Exhibit Display

Right upper lobe pneumonia

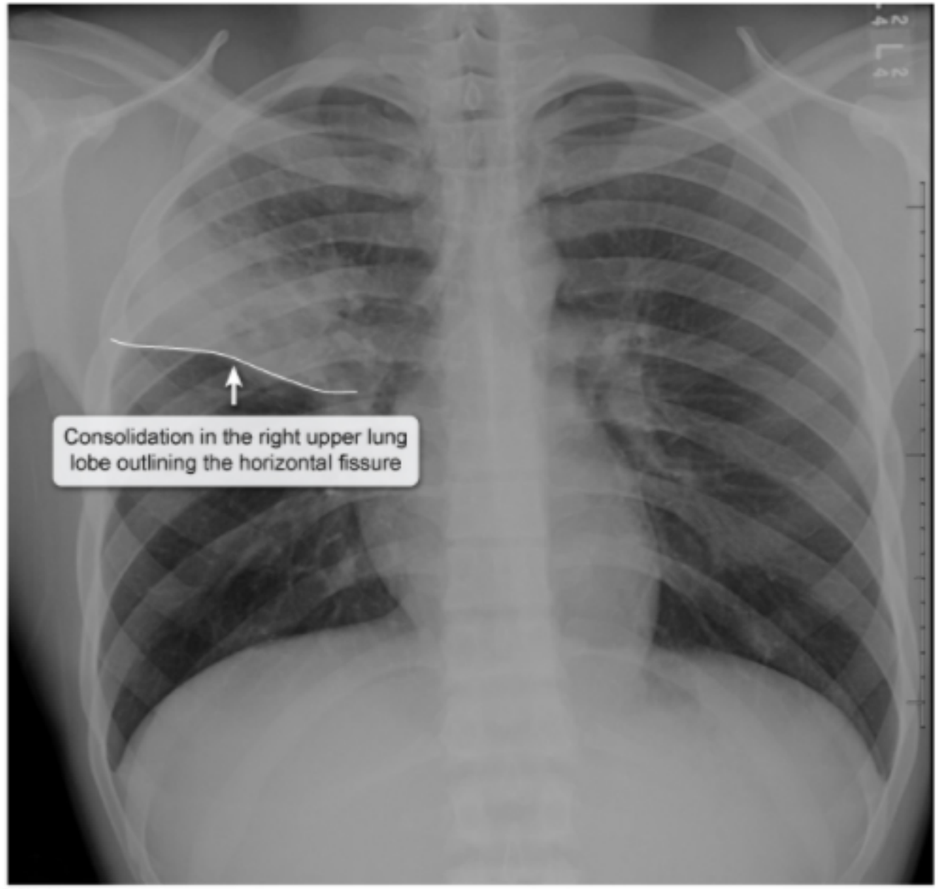

©UWorld

Zoom In Zoom Out Reset Add To Flash Card

pneumonia. Pulmonary consolidation occurs when the air in alveoli is replaced with a substance (eg, edema, pus, blood, cellular debris) that

Exhibit Display

Lingular (left upper lobe) pneumonia

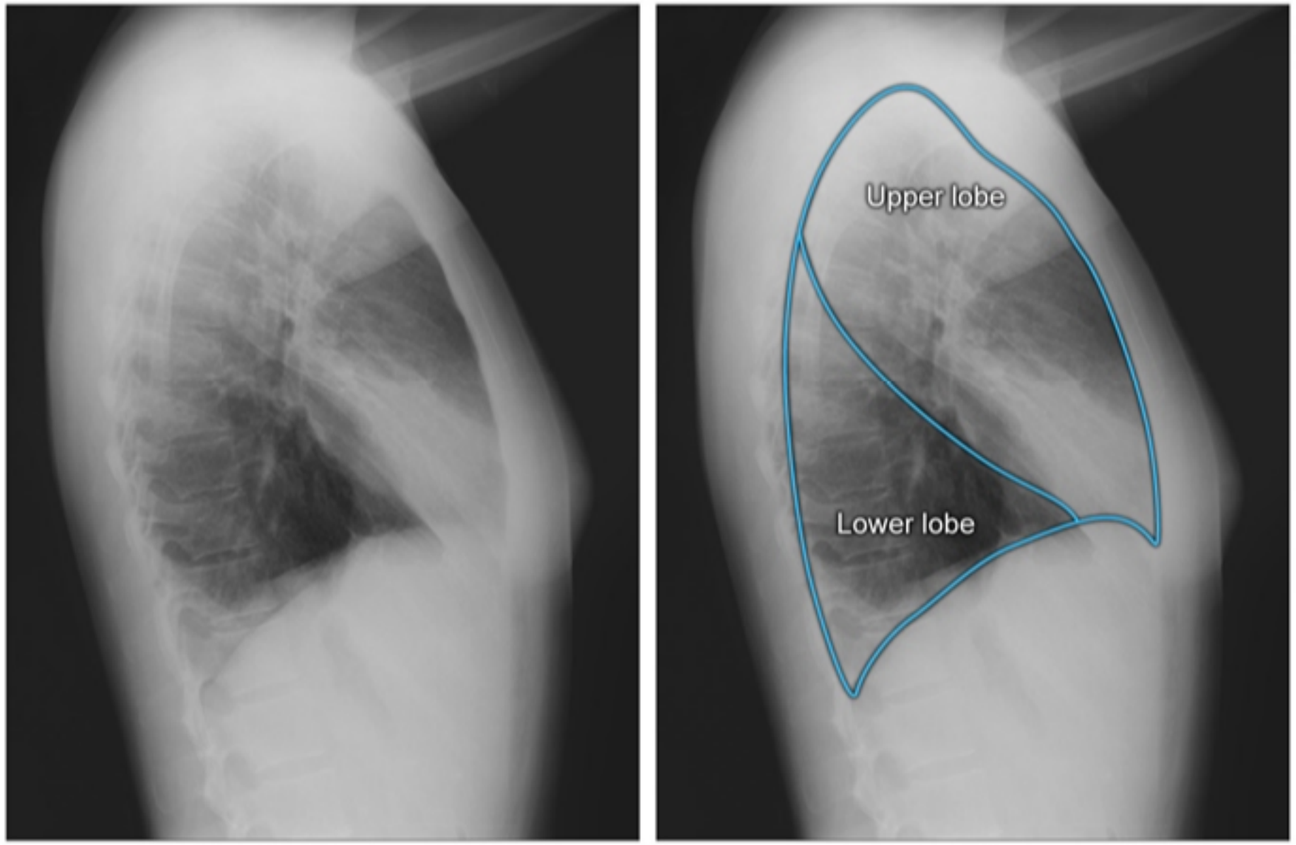

©UWorld

Zoom In Zoom Out Reset Add To Flash Card

pneumonia. Pulmonary consolidation occurs when the air in alveoli is replaced with a substance (eg, edema, pus, blood, cellular debris) that

Exhibit Display

Right middle lobe pneumonia Right Middle Lobe Pneumonia

Right middle lobe pneumonia

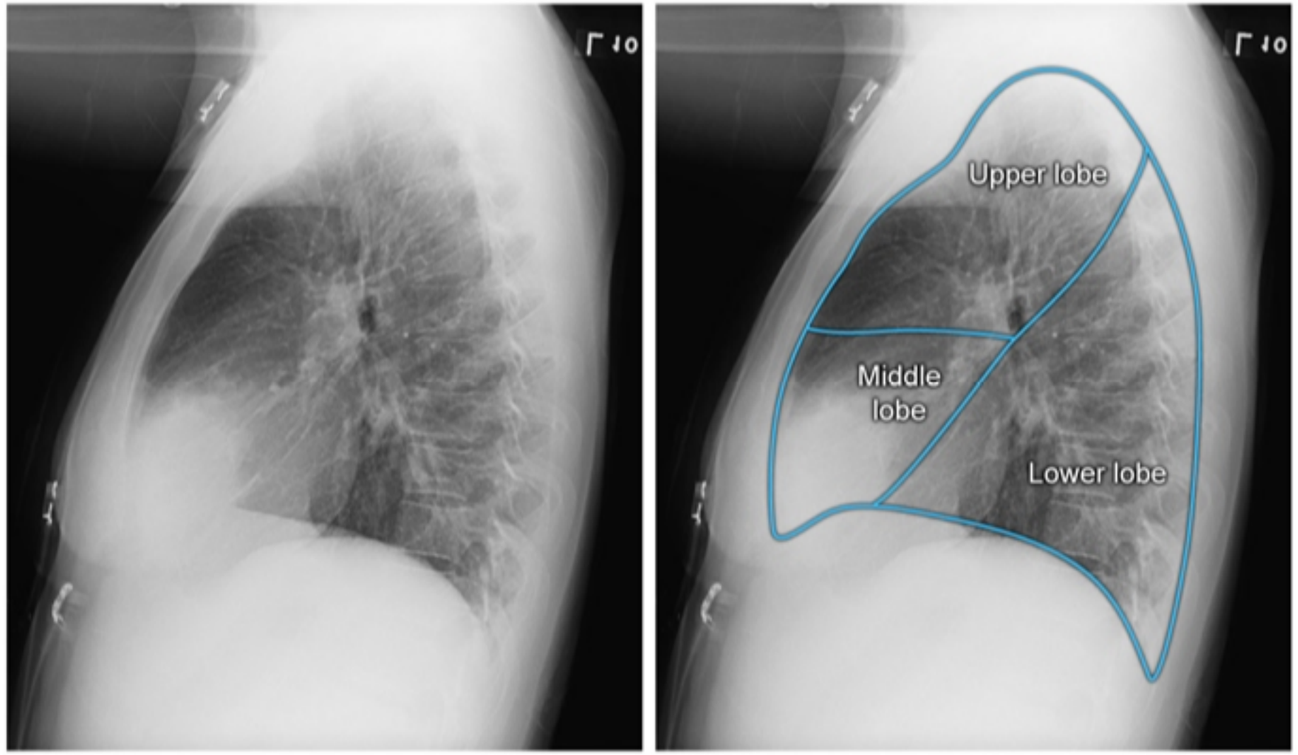

©UWorld

Zoom In Zoom Out Reset Add To Flash Card

pneumonia. Pulmonary consolidation occurs when the air in alveoli is replaced with a substance (eg, edema, pus, blood, cellular debris) that

Exhibit Display

Right middle lobe pneumonia Right Middle Lobe Pneumonia

Right middle lobe pneumonia

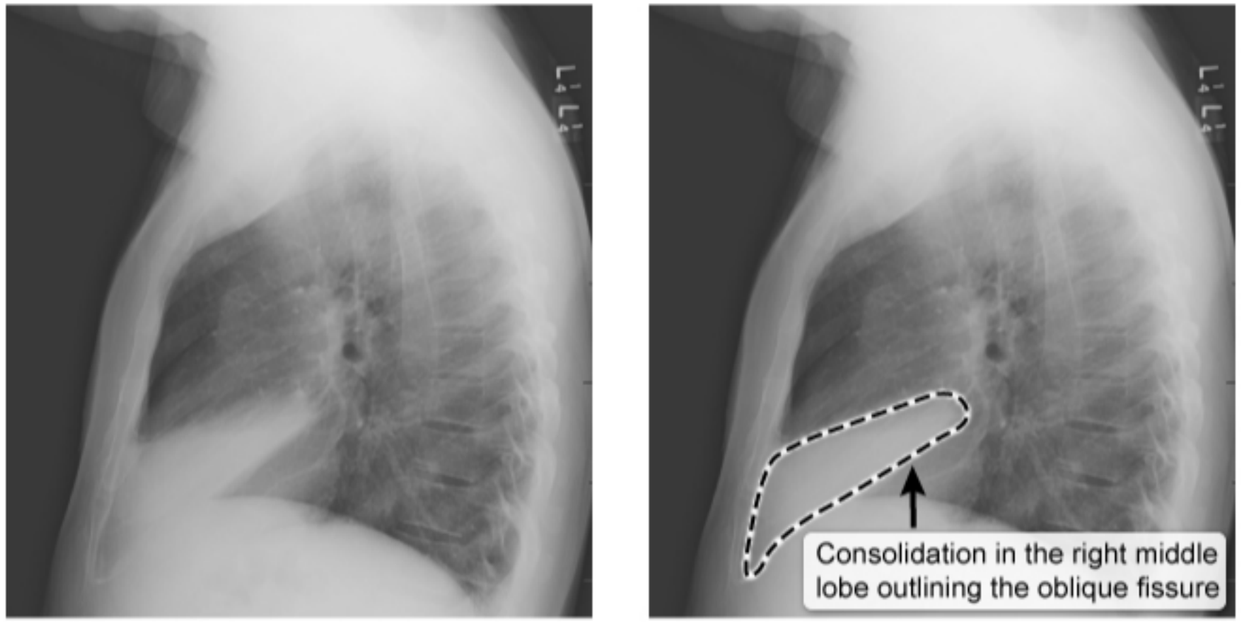

© UWorld

Zoom In Zoom Out Reset Add To Flash Card

pneumonia. Pulmonary consolidation occurs when the air in alveoli is replaced with a substance (eg, edema, pus, blood, cellular debris) that

Exhibit Display

Unilateral left pleural effusion Unilateral pleural effusion (secondary to malignancy)

Unilateral pleural effusion

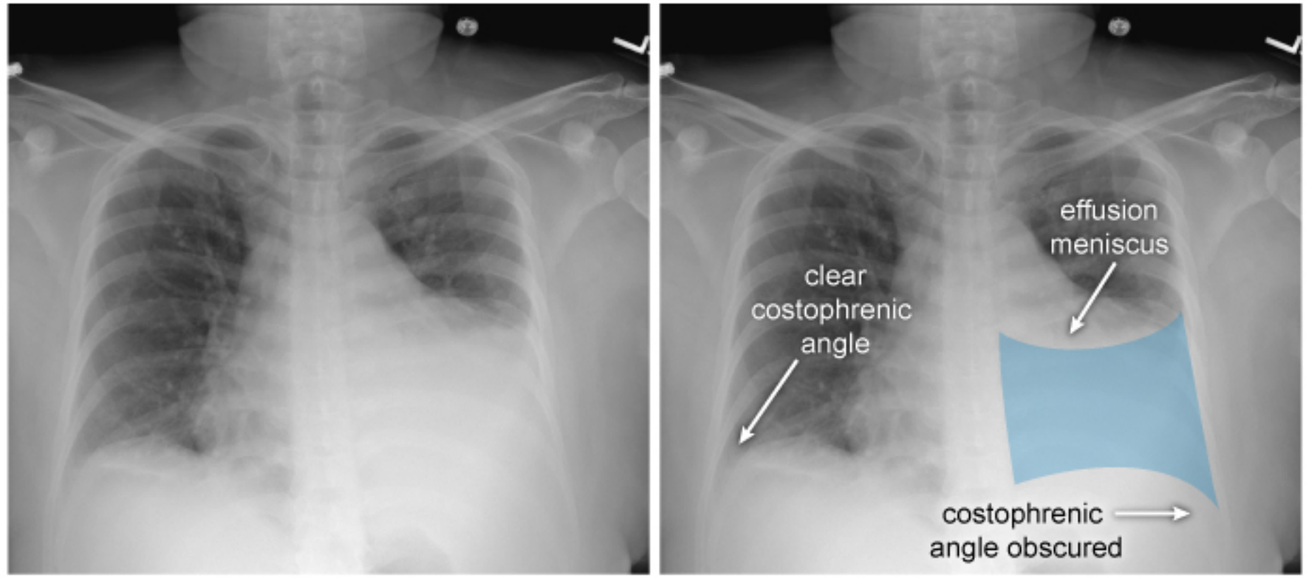

©UWorld

Zoom In Zoom Out Reset Add To Flash Card

pneumonia. Pulmonary consolidation occurs when the air in alveoli is replaced with a substance (eg, edema, pus, blood, cellular debris) that

Exhibit Display

Unilateral left pleural effusion Unilateral pleural effusion (secondary to malignancy)

Unilateral pleural effusion

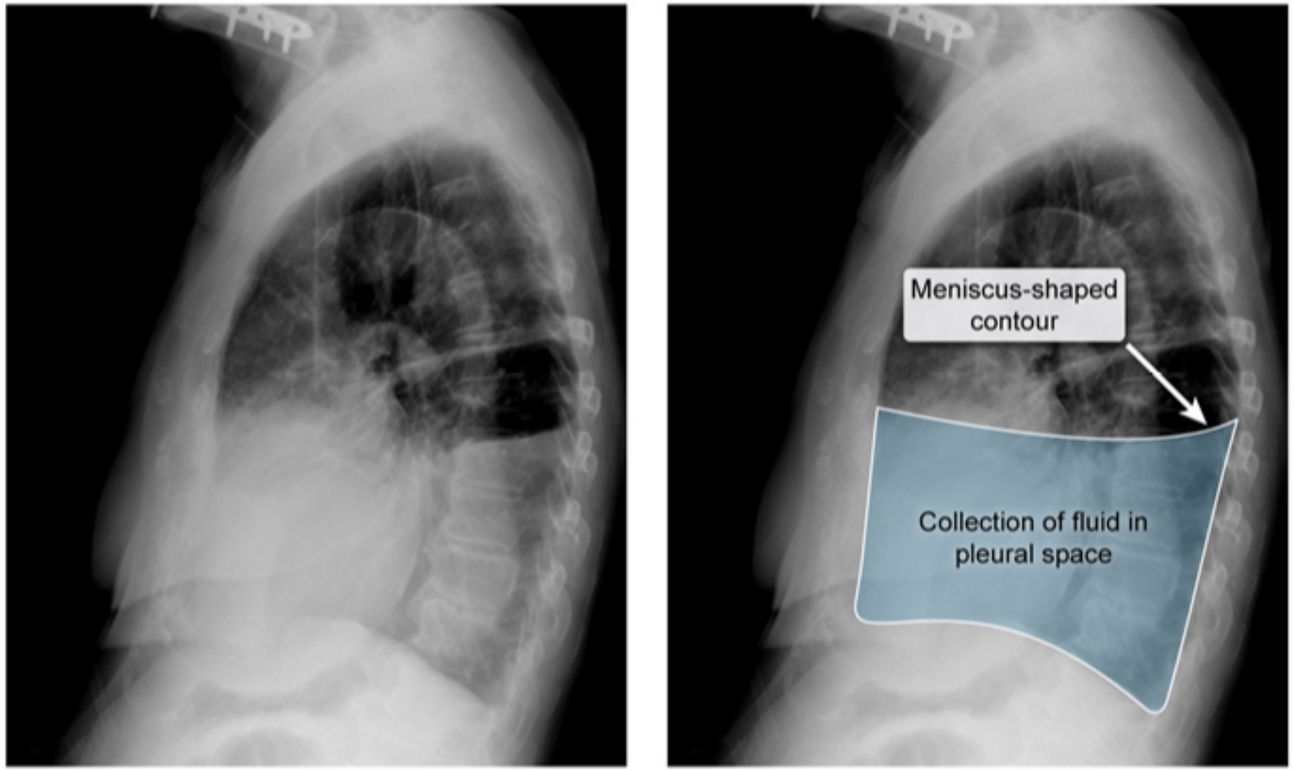

©UWorld

Zoom In Zoom Out Reset Add To Flash Card

A 21-year-old man comes to the emergency department after suffering an injury during a football game. He was falling to the ground when he was struck forcefully from behind by the helmet of an opposing player. The patient was able to ambulate after the injury but has since had severe pain worsened by deep breaths. His blood pressure is 110/65 mm Hg, pulse is 110/min, and respirations are 16/min. On examination, there is bruising and tenderness over the left posterior chest wall. There is normal spinal range of motion and no midline tenderness. Gait and lower extremity neurologic examination are normal. Imaging studies reveal a fracture of the left 12th rib. Which of the following structures is most likely to be lacerated by the fractured bone?

A. Left hepatic lobe

B. Left kidney

C. Pancreas

D. Spleen

E. Visceral pleura

Submit

A 21-year-old man comes to the emergency department after suffering an injury during a football game. He was falling to the ground when he was struck forcefully from behind by the helmet of an opposing player. The patient was able to ambulate after the injury but has since had severe pain worsened by deep breaths. His blood pressure is 110/65 mm Hg, pulse is 110/min, and respirations are 16/min. On examination, there is bruising and tenderness over the left posterior chest wall. There is normal spinal range of motion and no midline tenderness. Gait and lower extremity neurologic examination are normal. Imaging studies reveal a fracture of the left 12th rib. Which of the following structures is most likely to be lacerated by the fractured bone?

A. Left hepatic lobe (1%)
✓ B. Left kidney (55%)
C. Pancreas (0%)
D. Spleen (33%)
E. Visceral pleura (8%)

Omitted
Correct answer
B

55%
Answered correctly

03 secs
Time Spent

01/19/2020
Last Updated

Explanation

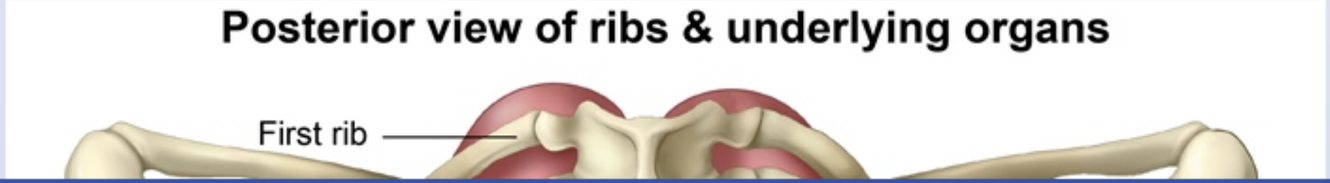

Posterior view of ribs & underlying organs

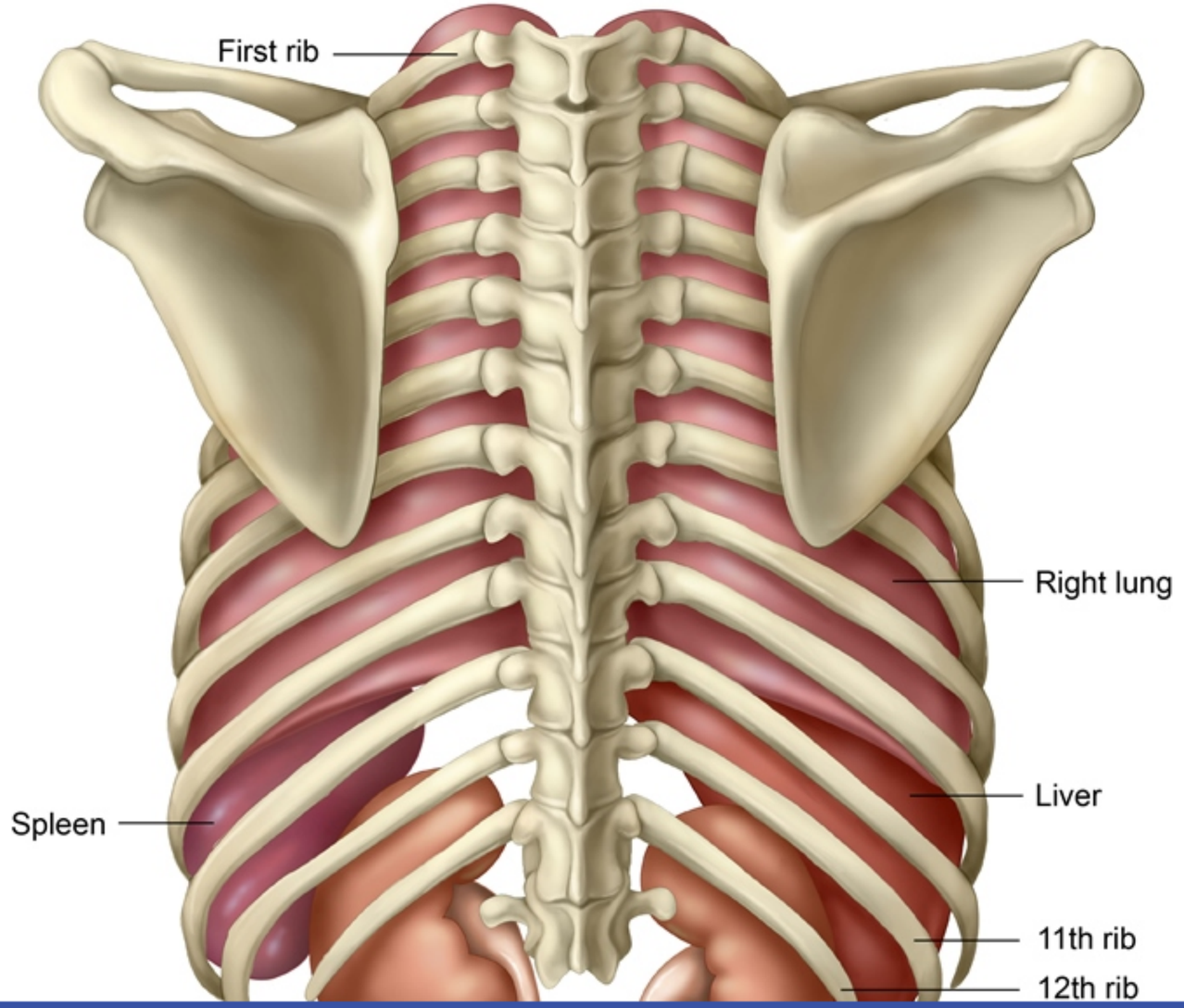

1
2
3
4
5
6
7
8
9
10
11
12
13
14
15

Posterior view of ribs & underlying organs

Exhibit Display

Posterior view of ribs & underlying organs

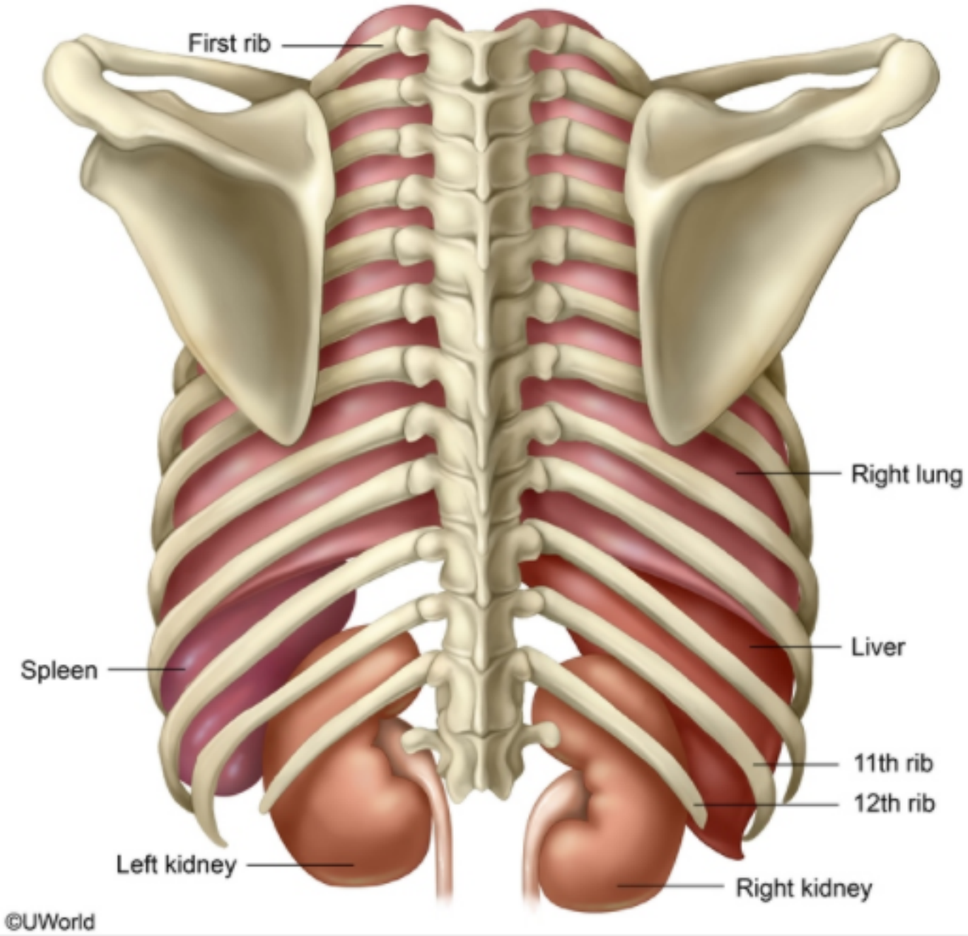

Zoom In | Zoom Out | Reset | Add To New Card | Existing Card

Left kidney

The first 7 rib pairs are considered "true" ribs because their costal cartilage attaches directly to the sternum; the cartilage of the lower 5 pairs does not, and they are considered "false" ribs. Of these, the cartilage of ribs 8-10 attaches to the costal cartilage of the upper ribs. The 11th and 12th ribs are "floating" ribs, meaning that they are not bound to the anterior rib cage by cartilage.

The **left 12th rib** overlies the parietal pleura medially and the **kidney** laterally. For this reason, the distal tip of the left 12th rib can be displaced into the retroperitoneum when fractured, lacerating the left kidney.

(Choice A) The liver occupies much of the right upper quadrant of the abdominal cavity, where the 8th-11th ribs overlie the liver's posterior surface. The left lobe crosses the midline antero-inferior to the diaphragm, where it is not vulnerable to a displaced fragment from the 12th rib.

(Choice C) The pancreas is a partially retroperitoneal organ that overlies the body of the second lumbar vertebra. Crushing abdominal trauma is the injury most likely to cause pancreatic damage.

(Choice D) The spleen lies in the posterior superior portion of the left abdominal cavity. The left 9th, 10th, and 11th ribs overlie the spleen.

(Choice E) The visceral pleura envelop the lungs. At rest, the inferior margin of the left lung lies at the level of the 10th rib in the mid-scapular line. During maximal inhalation, the lung may descend to the level of the most medial portion of the 12th rib, but fractures of ribs 1-6 have the greatest chance of damaging the visceral pleura.

Educational objective:
The left kidney lies immediately deep to the tip of the 12th rib.

Anatomy	Renal, Urinary Systems & Electrolytes	Rib fracture
Subject	System	Topic

Copyright © UWorld. All rights reserved.

12th rib

Exhibit Display

Rib cage, anterior view

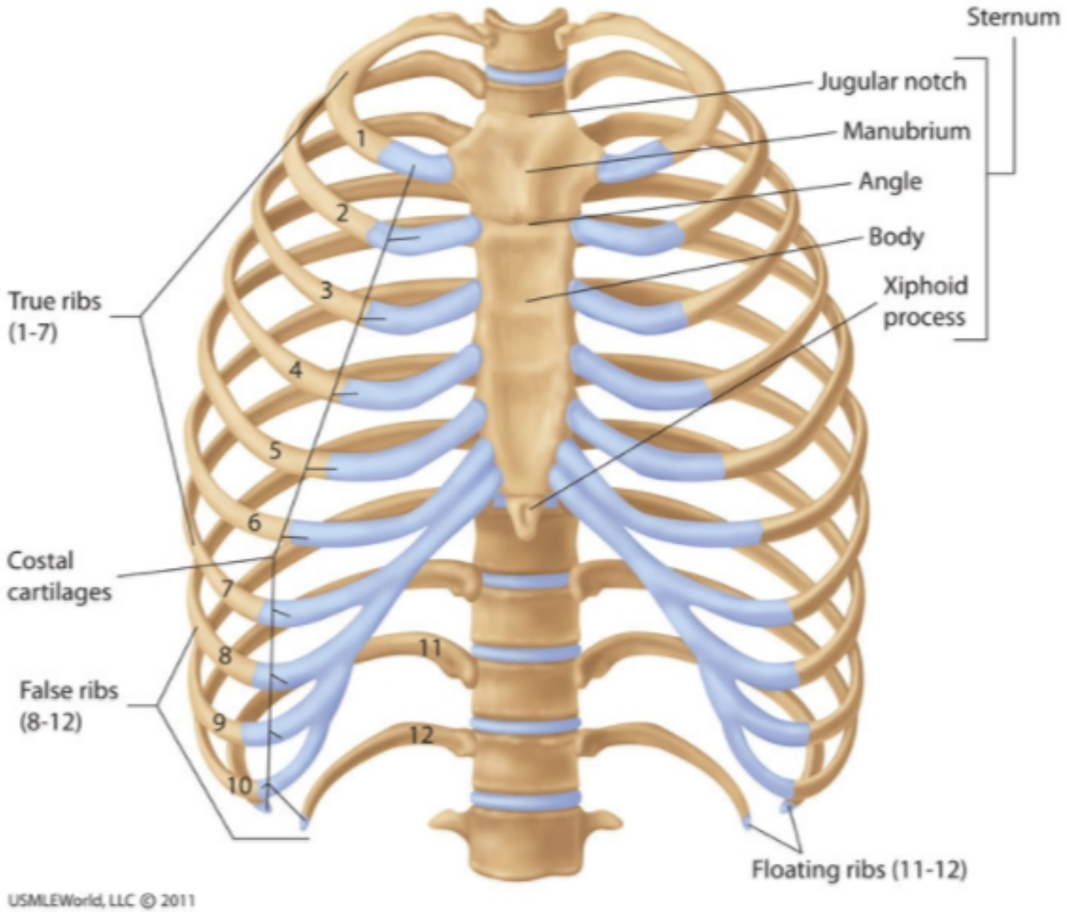

Zoom In | Zoom Out | Reset | Add To New Card | Existing Card

A 48-year-old woman comes to the office with a 6-month history of involuntary passage of a few drops of urine when sneezing or coughing. She has recently been leaking even more urine with minimal activity, which has been embarrassing and has caused her to limit her social activities. The patient has no weakness, numbness, or fecal incontinence. She has a history of hypertension and type 2 diabetes mellitus. She does not use tobacco, alcohol, or illicit drugs. She is married and has 4 children. Her supine blood pressure is 126/82 mm Hg and her upright blood pressure is 120/80 mm Hg. External genitalia examination shows leakage of a small amount of urine from the urethra when the patient is asked to cough. Neurological examination is within normal limits. Which of the following is the most likely cause of her condition?

A. Detrusor muscle inactivity
B. Detrusor muscle overactivity
C. Diabetic autonomic neuropathy
D. Small frontal lobe infarct
E. Urethral obstruction from a tumor
F. Urethral sphincter dysfunction

Submit

A 48-year-old woman comes to the office with a 6-month history of involuntary passage of a few drops of urine when sneezing or coughing. She has recently been leaking even more urine with minimal activity, which has been embarrassing and has caused her to limit her social activities. The patient has no weakness, numbness, or fecal incontinence. She has a history of hypertension and type 2 diabetes mellitus. She does not use tobacco, alcohol, or illicit drugs. She is married and has 4 children. Her supine blood pressure is 126/82 mm Hg and her upright blood pressure is 120/80 mm Hg. External genitalia examination shows leakage of a small amount of urine from the urethra when the patient is asked to cough. Neurological examination is within normal limits. Which of the following is the most likely cause of her condition?

- A. Detrusor muscle inactivity (9%)
- B. Detrusor muscle overactivity (10%)
- C. Diabetic autonomic neuropathy (11%)
- D. Small frontal lobe infarct (0%)
- E. Urethral obstruction from a tumor (0%)
- ✓ F. Urethral sphincter dysfunction (67%)

Omitted
Correct answer
F

67%
Answered correctly

02 secs
Time Spent

03/23/2020
Last Updated

Explanation

Differential diagnosis of urinary incontinence		
	Etiology	Symptoms

Differential diagnosis of urinary incontinence		
	Etiology	**Symptoms**
Stress	↓ Urethral sphincter tone Urethral hypermobility	Leakage with coughing, lifting, sneezing
Urge	Detrusor hyperactivity	Sudden, overwhelming urge to urinate
Overflow	Impaired detrusor contractility Bladder outlet obstruction	Incomplete emptying & persistent involuntary dribbling

This patient's presentation is consistent with stress incontinence, which is due to urethral sphincter dysfunction. The internal urethral sphincter is mainly smooth muscle controlled by the autonomic nervous system (sympathetic - contraction, parasympathetic - relaxation). The external urethral sphincter (EUS) is mostly pelvic floor skeletal muscle under voluntary control. Bladder emptying is mainly due to detrusor muscle contraction, while continence is maintained by the urethral sphincters. During bladder filling, sympathetic activation closes the internal sphincter and inhibits detrusor contraction. Parasympathetic stimulation causes detrusor muscle contraction and internal sphincter relaxation but the urine is held in check by the EUS. Incompetence of the urethral sphincter (mainly EUS) is a major factor causing incontinence.

Stress incontinence is the most common form of incontinence and typically presents after age 45. Patients have brief involuntary urine loss through the dysfunctional or weak urethral sphincter during activities (eg, coughing, sneezing, or vigorous effort) that increase abdominal pressure. It is almost twice as common in women because EUS trauma or pudendal nerve (innervates EUS) injury is common during vaginal child birth. Postmenopausal women have estrogen deficiency, which can cause laxity and weakness of pelvic floor support. Other risk factors for incontinence in women include obesity, co-morbidities (eg, diabetes, stroke), and genitourinary surgery (eg, hysterectomy).

(Choices A, C, and E) Overflow incontinence is due to impaired detrusor contractility (eg, diabetic autonomic neuropathy) or bladder outlet obstruction (eg, tumor obstructing urethra) causing incomplete bladder evacuation. Patients usually develop involuntary and continuous urinary leakage when the pressure inside the full bladder exceeds that of the sphincters. This patient's symptoms with activity and sneezing make these less likely.

(Choices B and D) Urge incontinence is due to detrusor overactivity that causes a sudden and/or frequent urge to urinate and empty the

This patient's presentation is consistent with stress incontinence, which is due to urethral sphincter dysfunction. The internal urethral sphincter is mainly smooth muscle controlled by the autonomic nervous system (sympathetic - contraction, parasympathetic - relaxation). The external urethral sphincter (EUS) is mostly pelvic floor skeletal muscle under voluntary control. Bladder emptying is mainly due to detrusor muscle contraction, while continence is maintained by the urethral sphincters. During bladder filling, sympathetic activation closes the internal sphincter and inhibits detrusor contraction. Parasympathetic stimulation causes detrusor muscle contraction and internal sphincter relaxation but the urine is held in check by the EUS. Incompetence of the urethral sphincter (mainly EUS) is a major factor causing incontinence.

Stress incontinence is the most common form of incontinence and typically presents after age 45. Patients have brief involuntary urine loss through the dysfunctional or weak urethral sphincter during activities (eg, coughing, sneezing, or vigorous effort) that increase abdominal pressure. It is almost twice as common in women because EUS trauma or pudendal nerve (innervates EUS) injury is common during vaginal child birth. Postmenopausal women have estrogen deficiency, which can cause laxity and weakness of pelvic floor support. Other risk factors for incontinence in women include obesity, co-morbidities (eg, diabetes, stroke), and genitourinary surgery (eg, hysterectomy).

(Choices A, C, and E) Overflow incontinence is due to impaired detrusor contractility (eg, diabetic autonomic neuropathy) or bladder outlet obstruction (eg, tumor obstructing urethra) causing incomplete bladder evacuation. Patients usually develop involuntary and continuous urinary leakage when the pressure inside the full bladder exceeds that of the sphincters. This patient's symptoms with activity and sneezing make these less likely.

(Choices B and D) Urge incontinence is due to detrusor overactivity that causes a sudden and/or frequent urge to urinate and empty the bladder. Triggers can include running water, hand washing, or exposure to cold weather. Loss of inhibitory central nervous system input to the bladder, due to frontal lobe and internal capsule infarcts, commonly cause detrusor hyperreflexia and urge incontinence. This patient's absence of a sudden urge to urinate makes these less likely.

Educational objective:
Stress incontinence is due to loss of pelvic floor support and incompetence of the urethral sphincter. Increased abdominal pressure (eg, coughing, sneezing, or vigorous effort) greater than the urethral sphincter pressure can cause brief involuntary urine loss, which is virtually diagnostic of stress incontinence.

References

- Stress Urinary Incontinence in Women: Diagnosis and Medical Management.

is held in check by the EUS. Incompetence of the urethral sphincter (mainly EUS) is a major factor causing incontinence.

Stress incontinence is the most common form of incontinence and typically presents after age 45. Patients have brief involuntary urine loss through the dysfunctional or weak urethral sphincter during activities (eg, coughing, sneezing, or vigorous effort) that increase abdominal pressure. It is almost twice as common in women because EUS trauma or pudendal nerve (innervates EUS) injury is common during vaginal child birth. Postmenopausal women have estrogen deficiency, which can cause laxity and weakness of pelvic floor support. Other risk factors for incontinence in women include obesity, co-morbidities (eg, diabetes, stroke), and genitourinary surgery (eg, hysterectomy).

(Choices A, C, and E) Overflow incontinence is due to impaired detrusor contractility (eg, diabetic autonomic neuropathy) or bladder outlet obstruction (eg, tumor obstructing urethra) causing incomplete bladder evacuation. Patients usually develop involuntary and continuous urinary leakage when the pressure inside the full bladder exceeds that of the sphincters. This patient's symptoms with activity and sneezing make these less likely.

(Choices B and D) Urge incontinence is due to detrusor overactivity that causes a sudden and/or frequent urge to urinate and empty the bladder. Triggers can include running water, hand washing, or exposure to cold weather. Loss of inhibitory central nervous system input to the bladder, due to frontal lobe and internal capsule infarcts, commonly cause detrusor hyperreflexia and urge incontinence. This patient's absence of a sudden urge to urinate makes these less likely.

Educational objective:
Stress incontinence is due to loss of pelvic floor support and incompetence of the urethral sphincter. Increased abdominal pressure (eg, coughing, sneezing, or vigorous effort) greater than the urethral sphincter pressure can cause brief involuntary urine loss, which is virtually diagnostic of stress incontinence.

References

- Stress Urinary Incontinence in Women: Diagnosis and Medical Management.

Anatomy	Renal, Urinary Systems & Electrolytes	Urinary incontinence
Subject	System	Topic

Copyright © UWorld. All rights reserved.

A 22-year-old man is brought to the emergency department after being involved in a fight at a nearby bar. The patient's respiratory rate is 28/min, blood pressure is 88/60 mm Hg, and heart rate is 114/min. Physical examination shows a penetrating right-sided stab wound along the upper surface of the clavicle between the lateral border of the sternum and the midclavicular line. Which of the following structures was most likely injured?

A. Accessory nerve

B. Ansa cervicalis

C. Carotid body

D. Inferior thyroid artery

E. Lung pleura

Submit

A 22-year-old man is brought to the emergency department after being involved in a fight at a nearby bar. The patient's respiratory rate is 28/min, blood pressure is 88/60 mm Hg, and heart rate is 114/min. Physical examination shows a penetrating right-sided stab wound along the upper surface of the clavicle between the lateral border of the sternum and the midclavicular line. Which of the following structures was most likely injured?

A. Accessory nerve (5%)
B. Ansa cervicalis (6%)
C. Carotid body (12%)
D. Inferior thyroid artery (6%)
✓ E. Lung pleura (68%)

Omitted
Correct answer
E

68%
Answered correctly

02 secs
Time Spent

04/16/2020
Last Updated

Explanation

Normal chest x-ray

Normal chest x-ray

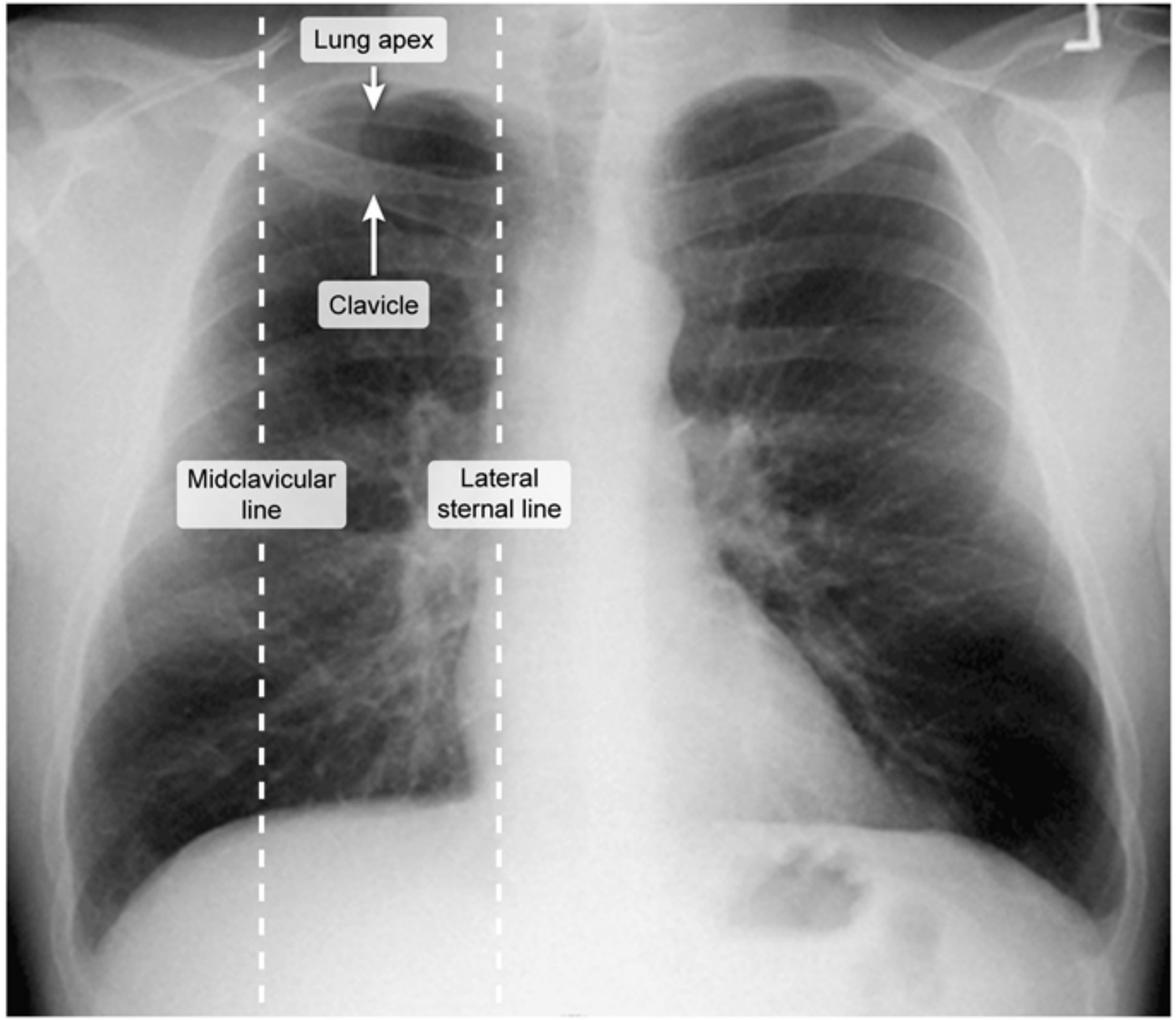

©UWorld

In patients with neck injuries, it is important to remember that the **lung apices** and cervical pleura extend **above the clavicle and first rib** through the superior thoracic aperture. Stab wounds immediately above the clavicle and lateral to the manubrium can puncture the pleura and cause pneumothorax, tension pneumothorax, or hemothorax.

This patient most likely has a **tension pneumothorax** as a result of his pleural injury. As an increasing volume of air accumulates within the pleural space, the lungs and mediastinum deviate to the opposite side of the chest. Increased pressure within the chest cavity decreases systemic venous return to the heart, **lowering cardiac output**. Signs and symptoms of tension pneumothorax include tachycardia, **hypotension**, tachypnea, hypoxemia, and hyperresonance to percussion and absence of breath sounds on the affected side. Treatment is with emergency needle thoracostomy or chest tube.

(Choice A) The accessory nerve (cranial nerve XI) innervates the sternocleidomastoid and trapezius muscles. This nerve may be injured during surgery involving the posterior triangle of the neck (a region bounded by the sternocleidomastoid muscle, trapezius muscle, and clavicle).

(Choice B) The ansa cervicalis arises from the C1, C2, and C3 nerve roots and innervates the sternohyoid, sternothyroid, and omohyoid muscles of the anterior neck. Penetrating trauma to the neck above the cricoid cartilage can injure this nerve.

(Choice C) The carotid body, which contains O_2, CO_2, and H^+ chemoreceptors, lies at the bifurcation of the common carotid artery (just inferior to the hyoid bone).

(Choice D) The inferior thyroid artery arises from the thyrocervical trunk and courses posterior to the carotid artery and jugular vein to supply the inferior pole of the thyroid gland. Injury to the inferior thyroid artery is commonly associated with hoarseness because it runs adjacent to the recurrent laryngeal nerve.

Educational objective:
The lung apices extend above the level of the clavicle and first rib through the superior thoracic aperture. Penetrating injury in this area may lead to pneumothorax, tension pneumothorax, or hemothorax.

Anatomy	Pulmonary & Critical Care	Pneumothorax
Subject	System	Topic

Copyright © UWorld. All rights reserved.

©UWorld

Exhibit Display

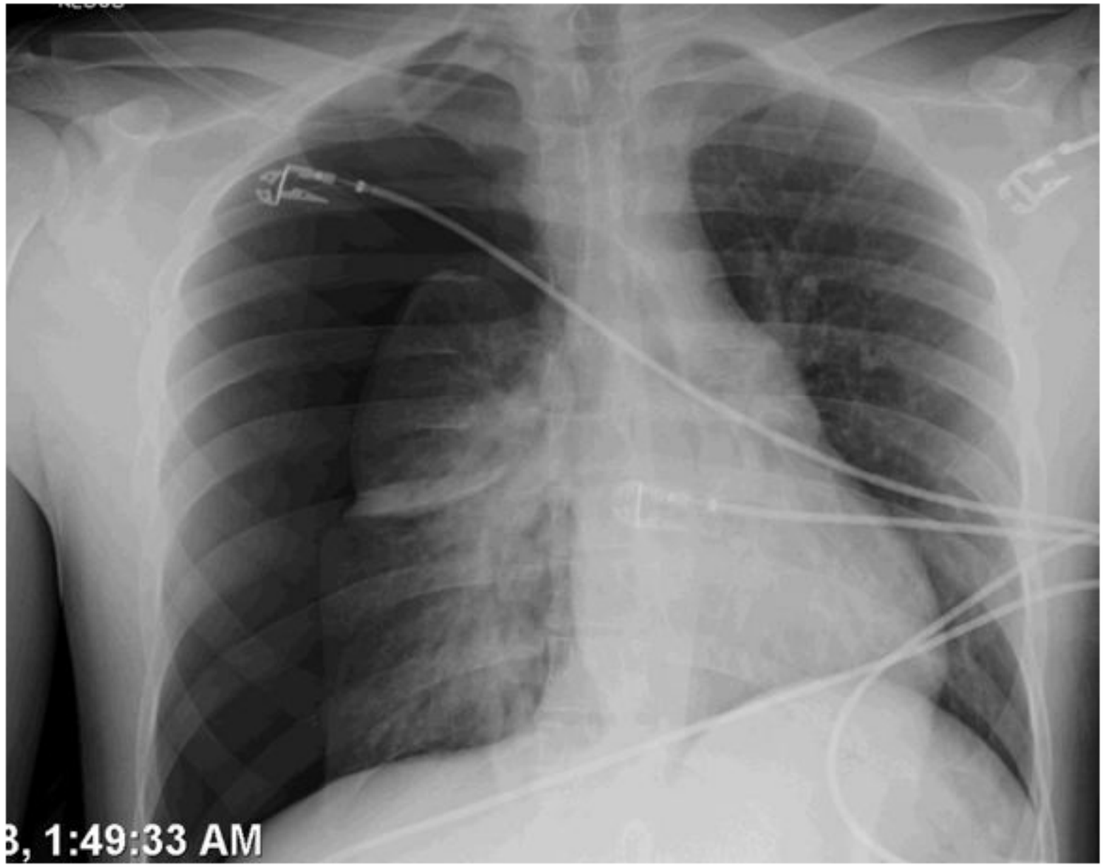

Zoom In
Zoom Out
Reset
Add To New Card | Existing Card

Copyright © UWorld. All rights reserved.

A 68-year-old man is evaluated in the hospital due to a pleural effusion. He has a history of base of tongue squamous cell carcinoma with involvement of multiple left anterior cervical lymph nodes. Two days ago, the patient underwent surgery to remove the tumor and the anterior cervical lymph nodes. Today, he has increasing shortness of breath, and chest x-ray reveals a large left pleural effusion. Which of the following was most likely injured during this patient's surgical procedure?

- A. Esophagus
- B. Innominate artery
- C. Lung parenchyma
- D. Phrenic nerve
- E. Thoracic duct
- F. Trachea

Submit

A 68-year-old man is evaluated in the hospital due to a pleural effusion. He has a history of base of tongue squamous cell carcinoma with involvement of multiple left anterior cervical lymph nodes. Two days ago, the patient underwent surgery to remove the tumor and the anterior cervical lymph nodes. Today, he has increasing shortness of breath, and chest x-ray reveals a large left pleural effusion. Which of the following was most likely injured during this patient's surgical procedure?

- A. Esophagus (1%)
- B. Innominate artery (3%)
- C. Lung parenchyma (13%)
- D. Phrenic nerve (20%)
- ✓ E. Thoracic duct (59%)
- F. Trachea (3%)

Omitted
Correct answer
E

59%
Answered correctly

02 secs
Time Spent

06/02/2020
Last Updated

Explanation

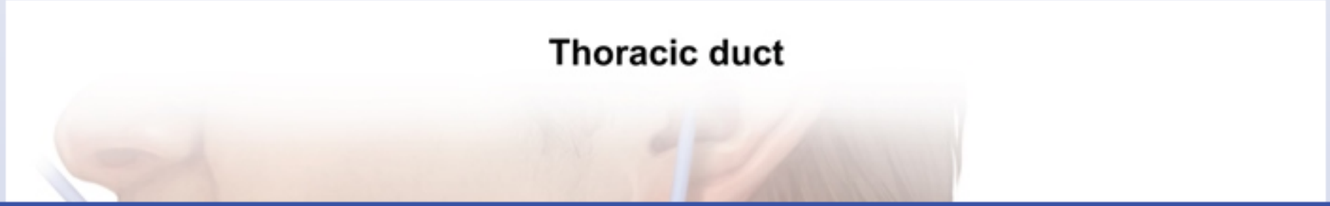

Thoracic duct

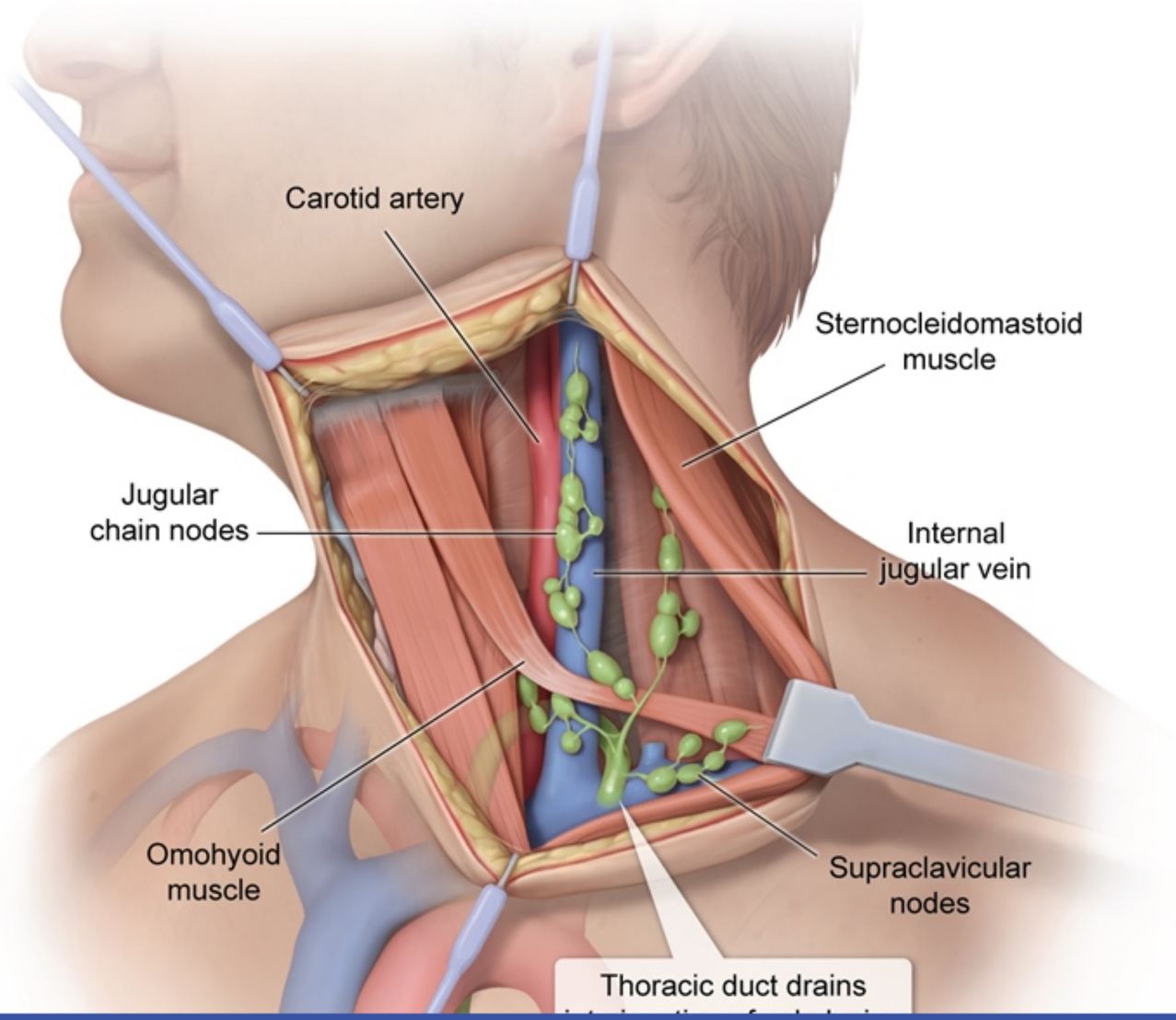

Exhibit Display

Thoracic duct

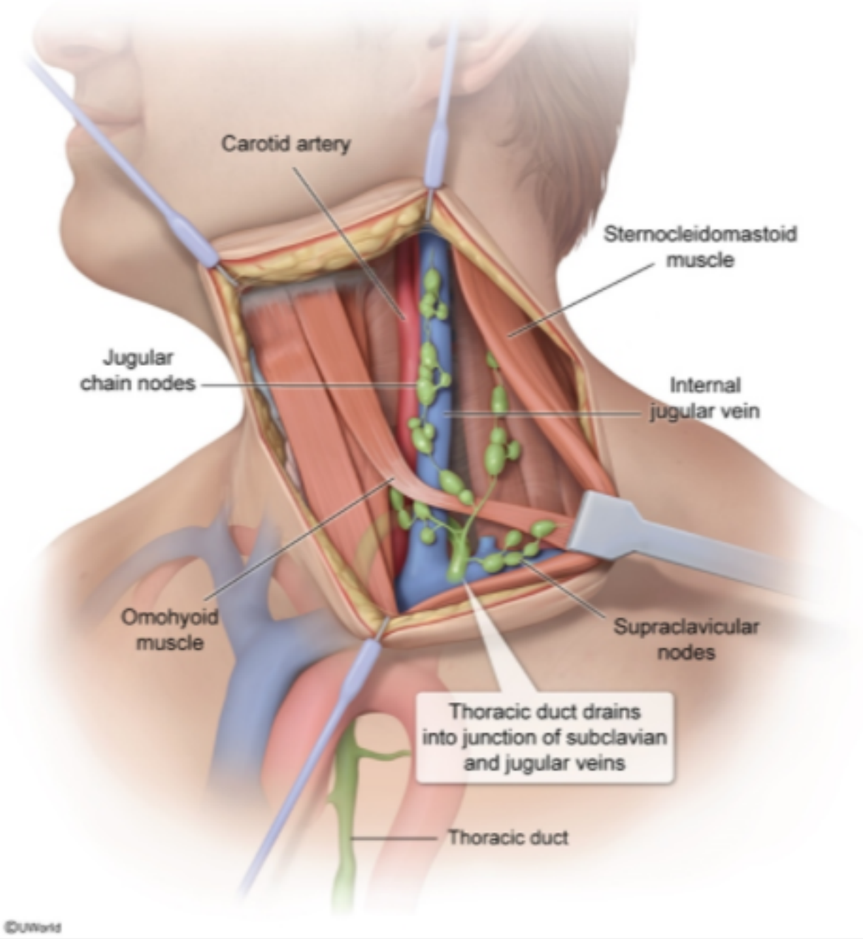

Zoom In
Zoom Out
Reset
Add To Flash Card

This patient with a pleural effusion 2 days after cervical lymph node removal most likely has a **chylothorax** due to intraoperative injury of the **thoracic duct**.

The thoracic duct is the largest lymphatic vessel. It originates at about the level of T12 in the abdomen where the lumbar and intestinal lymph trunks converge. It travels superiorly through the mediastinum (posterior to the esophagus) and drains into the **junction between the left subclavian and jugular veins** in the lower neck. It is most commonly injured during **thoracic procedures** (eg, esophagectomy) but can be injured in neck procedures as well (eg, cervical lymph node removal). Injury can result in leakage of lymph into either the neck or the thorax because a transected duct may retract into the chest.

The thoracic duct collects lymph from most of the body, including the abdominal viscera, the viscera of the left hemithorax, all tissue inferior to the umbilicus, and all left-sided tissues superior to the umbilicus (the right head, arm, and thorax drain into the much smaller right lymphatic duct).

(Choices A and F) The trachea and esophagus are deeper structures in the central neck that are covered by strap muscles; they are unlikely to be injured during removal of cervical lymph nodes in the lateral neck. In addition, although injury to the esophagus or trachea can cause pleural effusion, such injury is typically accompanied by air accumulation (eg, crepitus in the neck and/or pneumomediastinum).

(Choice B) The innominate artery is the first branch of the aortic arch, and it crosses the midtrachea from left to right (in the thorax). It does not travel through the left neck. In addition, injury to the innominate artery would cause massive blood loss, resulting in immediate hemodynamic instability.

(Choice C) The apex of the lung can project into the neck and be injured in some neck surgical procedures. However, injury would cause an acute pneumothorax rather than a slowly accumulating pleural effusion.

(Choice D) The phrenic nerve, which originates from C3-C5 and travels with the internal jugular vein, can be injured during neck procedures. However, such an injury would present with elevation of the hemidiaphragm.

Educational objective:
The thoracic duct carries lymph from most of the body and drains into the junction between the left subclavian and jugular veins. Although most commonly injured in thoracic procedures, it can also be injured in neck procedures where it travels through the neck. Injury may result in a chylothorax.

trunks converge. It travels superiorly through the mediastinum (posterior to the esophagus) and drains into the **junction between the left subclavian and jugular veins** in the lower neck. It is most commonly injured during **thoracic procedures** (eg, esophagectomy) but can be injured in neck procedures as well (eg, cervical lymph node removal). Injury can result in leakage of lymph into either the neck or the thorax because a transected duct may retract into the chest.

The thoracic duct collects lymph from most of the body, including the abdominal viscera, the viscera of the left hemithorax, all tissue inferior to the umbilicus, and all left-sided tissues superior to the umbilicus (the right head, arm, and thorax drain into the much smaller right lymphatic duct).

(Choices A and F) The trachea and esophagus are deeper structures in the central neck that are covered by strap muscles; they are unlikely to be injured during removal of cervical lymph nodes in the lateral neck. In addition, although injury to the esophagus or trachea can cause pleural effusion, such injury is typically accompanied by air accumulation (eg, crepitus in the neck and/or pneumomediastinum).

(Choice B) The innominate artery is the first branch of the aortic arch, and it crosses the midtrachea from left to right (in the thorax). It does not travel through the left neck. In addition, injury to the innominate artery would cause massive blood loss, resulting in immediate hemodynamic instability.

(Choice C) The apex of the lung can project into the neck and be injured in some neck surgical procedures. However, injury would cause an acute pneumothorax rather than a slowly accumulating pleural effusion.

(Choice D) The phrenic nerve, which originates from C3-C5 and travels with the internal jugular vein, can be injured during neck procedures. However, such an injury would present with elevation of the hemidiaphragm.

Educational objective:
The thoracic duct carries lymph from most of the body and drains into the junction between the left subclavian and jugular veins. Although most commonly injured in thoracic procedures, it can also be injured in neck procedures where it travels through the neck. Injury may result in a chylothorax.

Anatomy	Pulmonary & Critical Care	Pleural effusion
Subject	System	Topic

Copyright © UWorld. All rights reserved.

A 65-year-old man comes to the emergency department due to severe lower abdominal pain and nausea. He also has not been able to urinate for the past 24 hours. The patient has a history of hypertension and benign prostatic hyperplasia. On examination, a large mass is palpable in the suprapubic area. Multiple attempts at urethral catheterization are unsuccessful, and an ultrasound-guided midline suprapubic cystostomy is planned. Besides the bladder wall, which of the following structures is most likely to be penetrated by the trocar and cannula during the procedure?

A. Anterior abdominal aponeurosis

B. Parietal peritoneum

C. Perineal membrane

D. Ureter

E. Visceral peritoneum

Submit

A 65-year-old man comes to the emergency department due to severe lower abdominal pain and nausea. He also has not been able to urinate for the past 24 hours. The patient has a history of hypertension and benign prostatic hyperplasia. On examination, a large mass is palpable in the suprapubic area. Multiple attempts at urethral catheterization are unsuccessful, and an ultrasound-guided midline suprapubic cystostomy is planned. Besides the bladder wall, which of the following structures is most likely to be penetrated by the trocar and cannula during the procedure?

- ✓ A. Anterior abdominal aponeurosis (53%)
- B. Parietal peritoneum (17%)
- C. Perineal membrane (8%)
- D. Ureter (5%)
- E. Visceral peritoneum (15%)

Omitted
Correct answer
A

53%
Answered correctly

02 secs
Time Spent

01/29/2020
Last Updated

Explanation

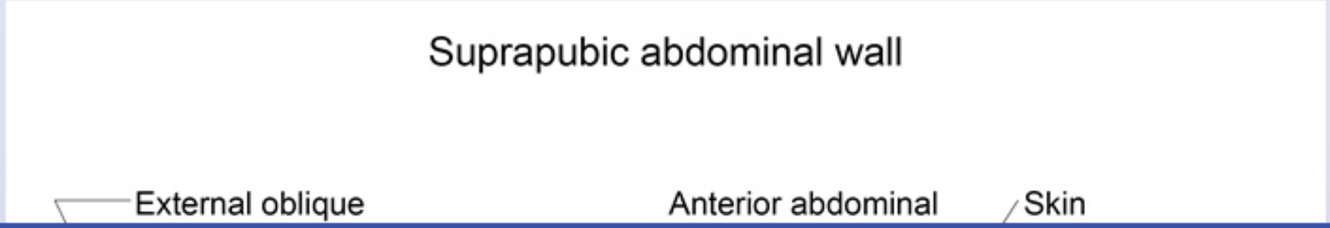

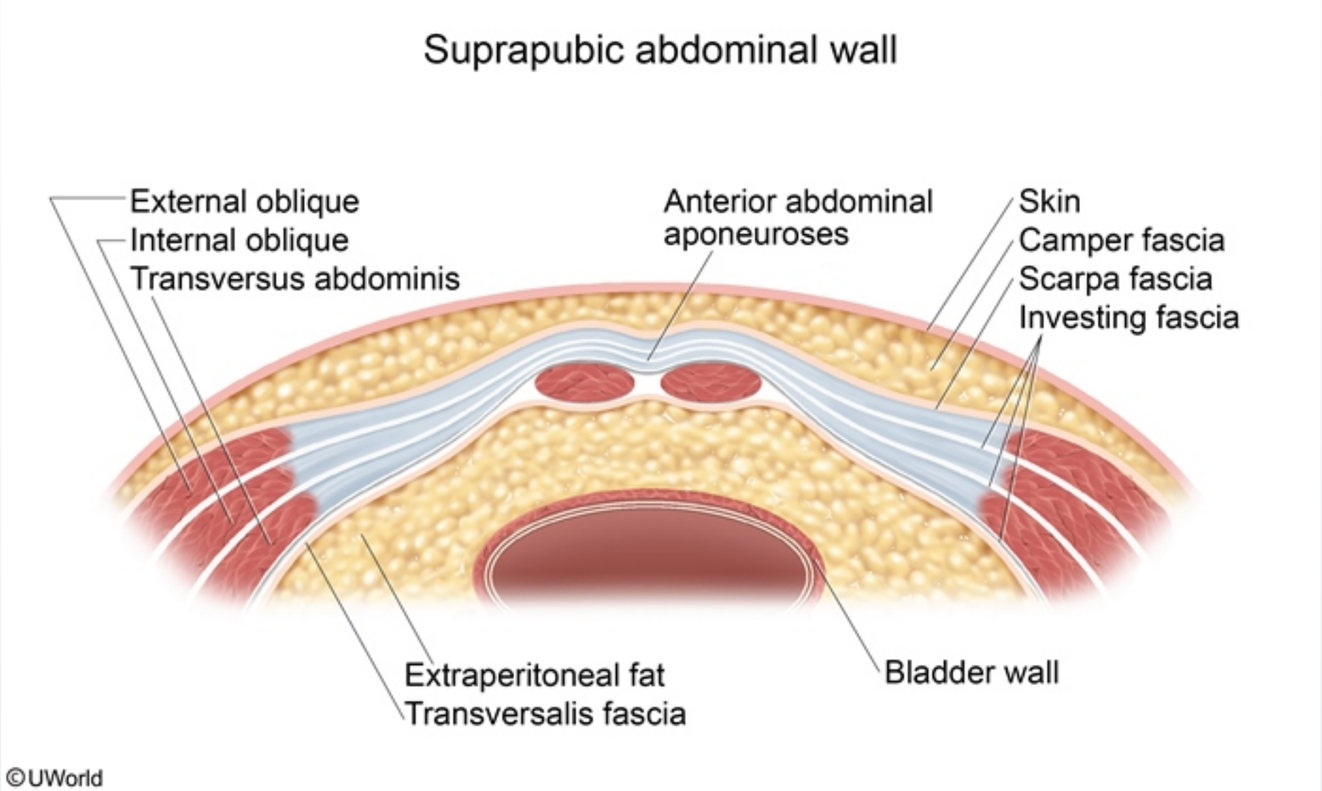

This patient has a severe bladder outlet obstruction, with the bladder palpable above the pelvic brim. The superior surface of the bladder is covered with peritoneum and is found below coils of ileum or sigmoid colon. Along the lateral margins of the bladder, the peritoneum is reflected onto the lateral pelvic walls. The **bladder** is therefore **extraperitoneal**. As the bladder fills and bulges upward, it comes into direct contact with the anterior abdominal wall anteroinferior to the peritoneal space.

In a **suprapubic cystostomy**, the trocar and cannula pierces the **aponeurosis** of the abdominal wall muscles, along with the layers of the superficial fascia, transversalis fascia, and extraperitoneal fat. However, the peritoneum is not entered **(Choices B and E)**, reducing the risk of peritonitis and hemoperitoneum.

(Choice C) The perineal membrane (inferior fascia of the urogenital diaphragm) spans the deep perineal pouch from the periosteum of the

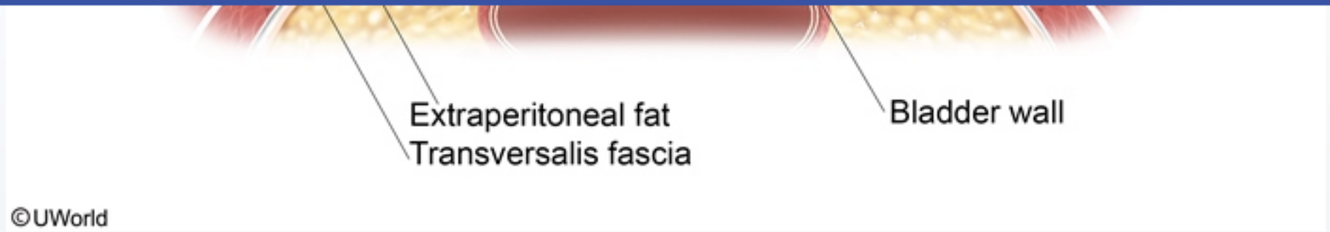

This patient has a severe bladder outlet obstruction, with the bladder palpable above the pelvic brim. The superior surface of the bladder is covered with peritoneum and is found below coils of ileum or sigmoid colon. Along the lateral margins of the bladder, the peritoneum is reflected onto the lateral pelvic walls. The **bladder** is therefore **extraperitoneal**. As the bladder fills and bulges upward, it comes into direct contact with the anterior abdominal wall anteroinferior to the peritoneal space.

In a **suprapubic cystostomy**, the trocar and cannula pierces the **aponeurosis** of the abdominal wall muscles, along with the layers of the superficial fascia, transversalis fascia, and extraperitoneal fat. However, the peritoneum is not entered **(Choices B and E)**, reducing the risk of peritonitis and hemoperitoneum.

(Choice C) The perineal membrane (inferior fascia of the urogenital diaphragm) spans the deep perineal pouch from the periosteum of the ischiopubic rami to the arcuate ligament of the pubis. It is penetrated by the urethra inferior to the bladder but would not be encountered in suprapubic cystostomy.

(Choice D) The ureters enter the bladder posterolaterally at the lateral angle of the bladder. A suprapubic trocar enters anteriorly and will not encounter the ureters unless it passes through the body of the bladder.

Educational objective:
The bladder is extraperitoneal. In placement of a suprapubic cystostomy, the trocar and cannula will pierce the layers of the abdominal wall but will not enter the peritoneum.

Anatomy	Renal, Urinary Systems & Electrolytes	Urinary retention
Subject	System	Topic

Copyright © UWorld. All rights reserved.

A 40-year-old nulligravida woman comes to the office with a 2-month history of worsening right pelvic pain. She experiences the pain daily, and its intensity does not vary during her menstrual cycle. In addition, the patient's waist size has increased despite a decreased appetite. Pelvic examination shows an irregularly shaped, fixed adnexal mass. One week later, she undergoes surgery to remove a large ovarian neoplasm. Within the true pelvis, the surgeon can most likely palpate the right ureter immediately anterior to which of the following structures?

A. Gonadal vein

B. Inferior vena cava

C. Internal iliac artery

D. Round ligament

E. Uterine artery

Submit

A 40-year-old nulligravida woman comes to the office with a 2-month history of worsening right pelvic pain. She experiences the pain daily, and its intensity does not vary during her menstrual cycle. In addition, the patient's waist size has increased despite a decreased appetite. Pelvic examination shows an irregularly shaped, fixed adnexal mass. One week later, she undergoes surgery to remove a large ovarian neoplasm. Within the true pelvis, the surgeon can most likely palpate the right ureter immediately anterior to which of the following structures?

- A. Gonadal vein (9%)
- B. Inferior vena cava (2%)
- ✓ C. Internal iliac artery (43%)
- D. Round ligament (13%)
- E. Uterine artery (30%)

Omitted
Correct answer
C

43%
Answered correctly

02 secs
Time Spent

05/04/2020
Last Updated

Explanation

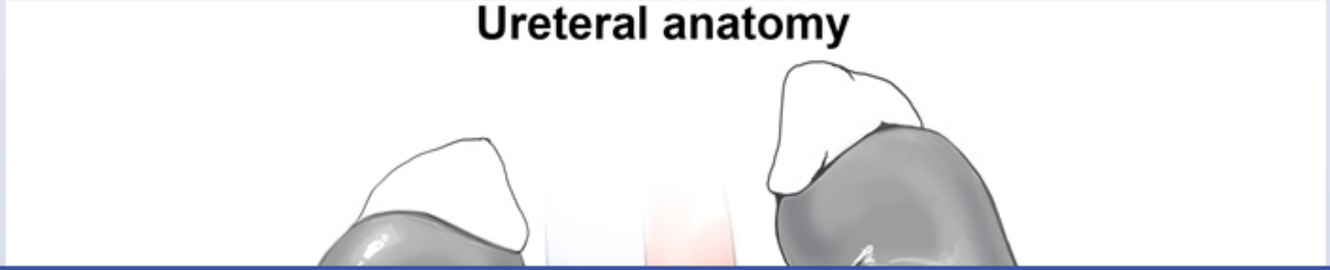

Ureteral anatomy

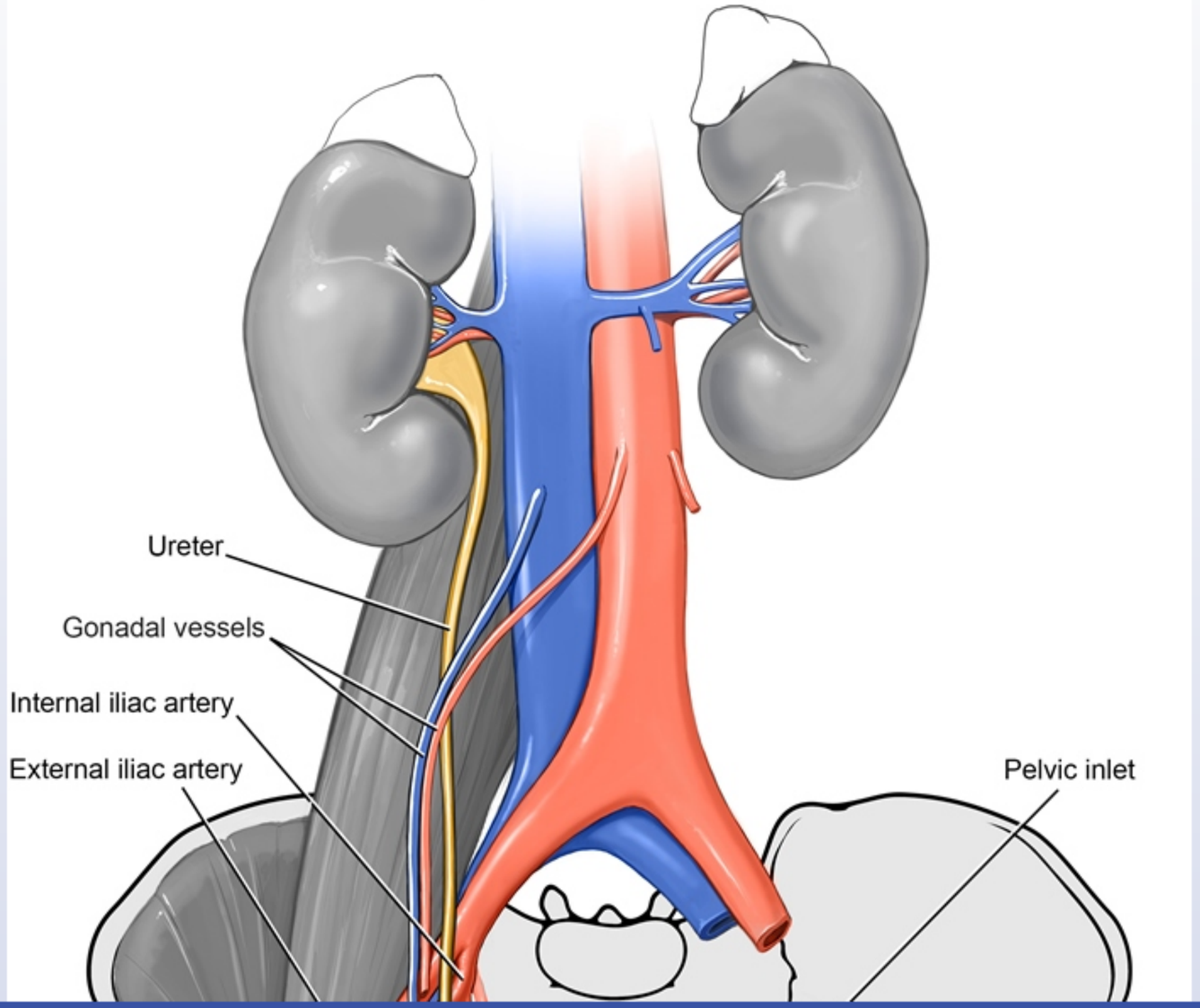

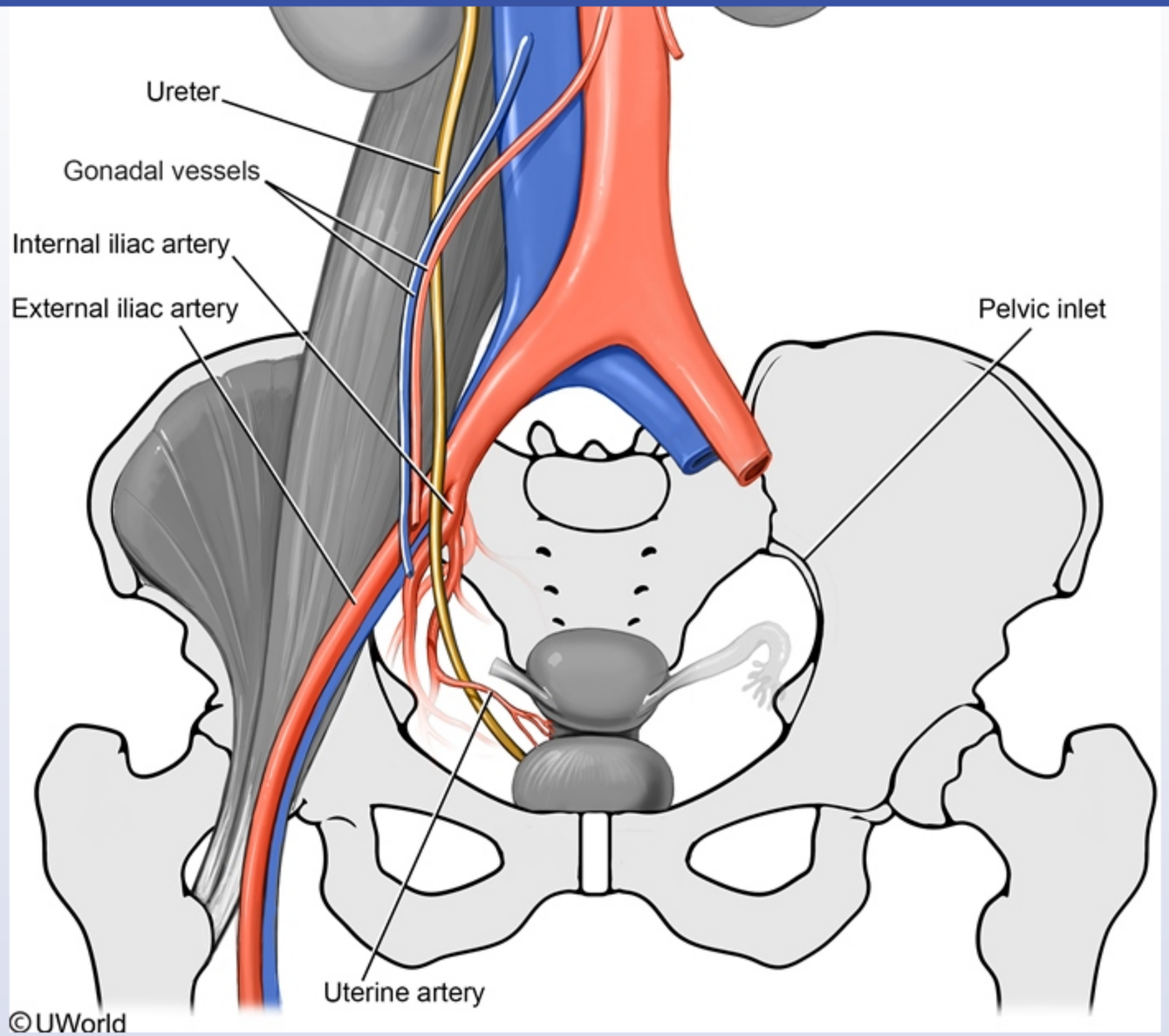
Ureter
Gonadal vessels
Internal iliac artery
External iliac artery
Pelvic inlet
Uterine artery
©UWorld

The **ureters** originate bilaterally at the renal pelvis and course inferiorly toward the bladder within the retroperitoneum just anterior to the psoas muscles. Midway from the kidney to the pelvic inlet, the ureters cross posterior to the gonadal artery and vein. The ureters then gain access to the pelvis by crossing anterior to the external iliac artery at, or just after, the bifurcation of the common iliac artery. At this point, the ureter lies medial to the ovarian vessels and **anterior to the internal iliac artery**.

Due to their course and proximity to other structures, the ureters are at particular risk for injury during pelvic and abdominal surgery.

(Choice A) The ureters cross posterior to the gonadal vessels within the retroperitoneum before entering the pelvis. In females, the ureters lie within the true pelvis medial to the ovarian vessels. In males, the testicular vessels never enter the true pelvis; instead, they pass around the pelvic brim before entering the deep ring of the inguinal canal.

(Choice B) The inferior vena cava rests on the right side of the vertebral bodies and is formed by the union of the common iliac veins at the L4 level. The internal and external iliac veins join to form the common iliac veins at the pelvic inlet.

(Choice D) The round ligaments of the uterus originate at the uterine fundus and course through the inguinal canal out to the labia majora. The ureters do not lie in close proximity.

(Choice E) The uterine artery courses within the cardinal ligament to reach the uterus. The ureters course along the uterosacral ligament and cross posterior to the uterine artery ("water under the bridge") before entering the bladder.

Educational objective:
The ureters pass posterior to the ovarian (gonadal) vessels within the retroperitoneum and cross anterior to the common/external iliac arteries to reach the true pelvis. Within the true pelvis, the ureters lie anterior to the internal iliac artery and posterior to the uterine artery.

Anatomy	Renal, Urinary Systems & Electrolytes	Ureter injury
Subject	System	Topic

Copyright © UWorld. All rights reserved.

1
2
3
4
5
6
7
8
9
10
11
12
13
14
15

Exhibit Display

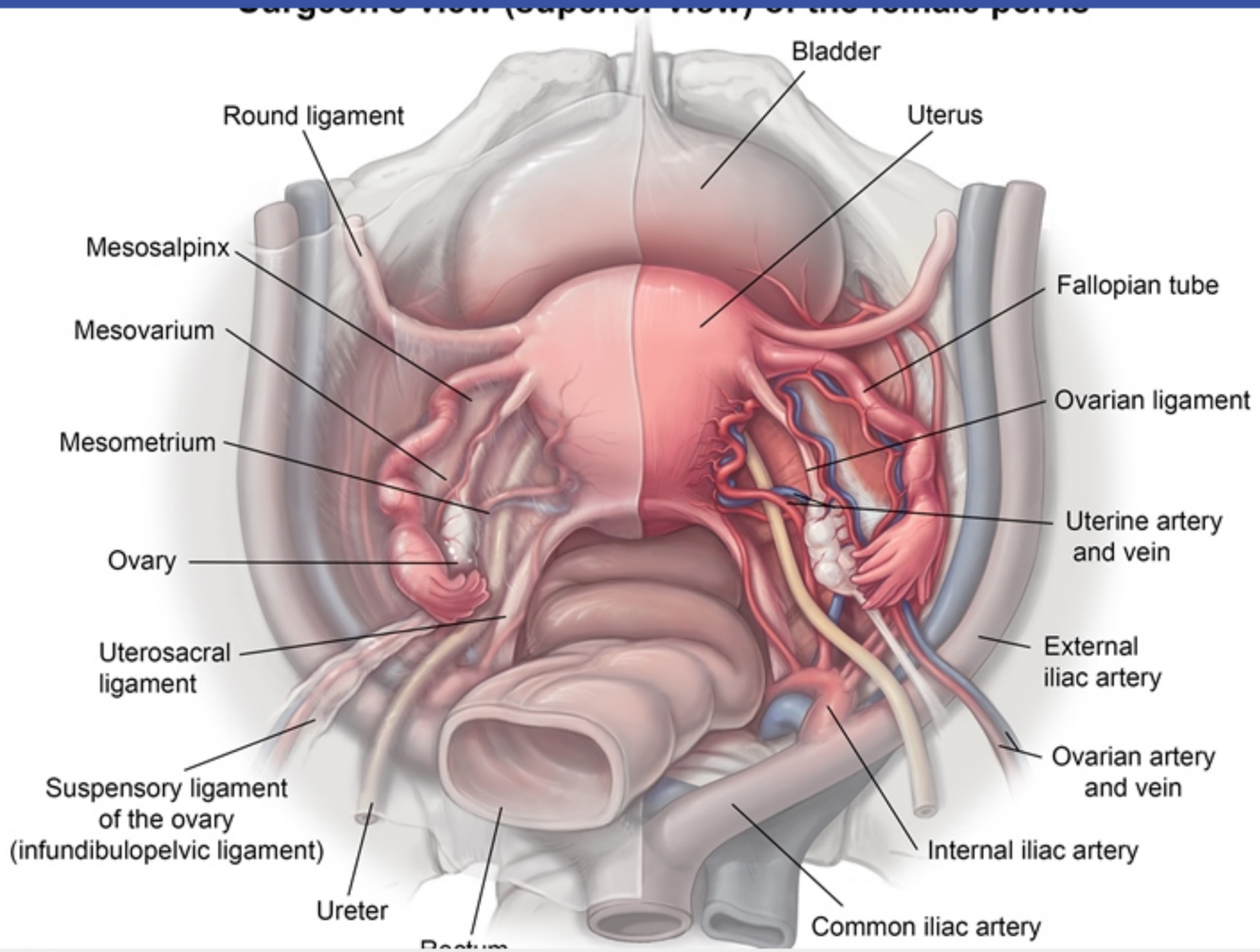

Zoom In | Zoom Out | Reset | Add To New Card | Existing Card